

# Erythematous lesions on the face of an 18-month-old girl

## Lesões eritematosas no rosto de uma menina de 18 meses

Margarida Brito-Caldeira\*, Célia Galhardas, and Juliana Baptista

Department of Dermatology and Venereology, Centro Hospitalar Universitário de Lisboa Central, Lisbon, Portugal

An 18-month-old girl was evaluated for pruritic facial lesions evolving over 2 months. She was healthy, with no personal or family dermatological history. She frequently visited her grandmother's farm, where she had contact with chickens and rabbits. Examination revealed a symmetrical, erythematous butterfly-shaped plaque occupying the central facial region, extending to the glabella and supraorbital areas, covered by yellowish scales (Fig. 1). The parents reported prior application of methylprednisolone aceponate cream, which worsened the dermatosis.

### What is the diagnosis?

#### *Tinea incognita*

A mycological examination showed septate filaments on direct microscopy. Microscopic examination of culture specimens identified clusters of microconidia and

spiral hyphae, consistent with *Trichophyton mentagrophytes* (var. *granulosum*). The diagnosis of *tinea incognita* (TI) was established.

TI is a dermatophytosis altered by topical corticosteroids or calcineurin inhibitors, masking its clinical features<sup>1</sup>. It commonly affects children aged 10-14 years and is rare in those under 3 years<sup>2,3</sup>. The face is frequently involved, as *tinea faciei* can be diagnostically challenging<sup>2,3</sup>. Hyphal invasion of hair follicles often necessitates oral antifungal treatment.

*T. mentagrophytes* var. *granulosum* is a zoophilic dermatophyte associated with rabbits and small rodents. The child's frequent contact with rabbits at her grandmother's farm likely facilitated fungal acquisition. The zoophilic nature of the variant explained the lesions' inflammatory and progressive features.

The child was treated with oral itraconazole (5 mg/kg/day) for 4 weeks, achieving complete resolution of the skin lesions.

#### \*Correspondence:

Margarida Caldeira

E-mail: margaridabcaldeira@gmail.com

2795-501X / © 2025 Portuguese Society of Dermatology and Venereology. Published by Permanyer. This is an open access article under the CC BY-NC-ND license (<http://creativecommons.org/licenses/by-nc-nd/4.0/>).

Received: 29-12-2024

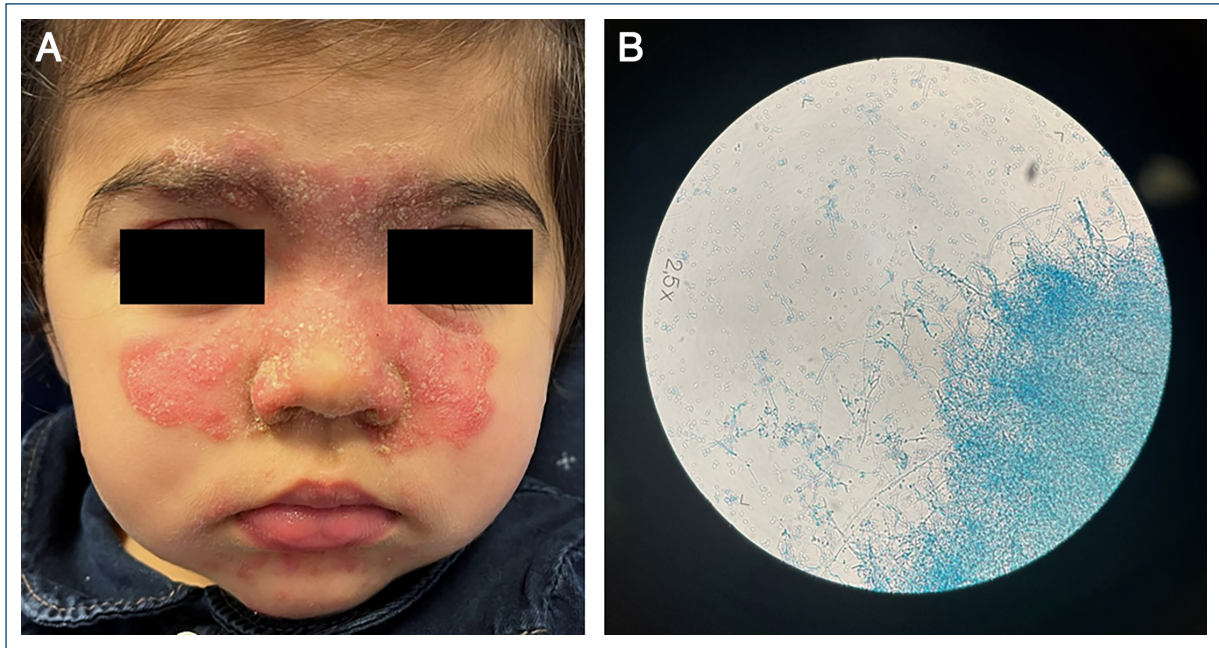
Accepted: 12-02-2025

DOI: 10.24875/PJDV.24000107

Available online: 22-01-2026

Port J Dermatol and Venereol. (ahead of print)

[www.portuguesejournalofdermatology.com](http://www.portuguesejournalofdermatology.com)



**Figure 1. A:** clinical findings showing erythematous butterfly-shaped plaque on the central facial region, covered by yellowish scales; **B:** microscopic examination of culture specimens identified clusters of microconidia and spiral hyphae, consistent with *Trichophyton mentagrophytes* (var. *granulosum*).

## Funding

None.

## Conflicts of interest

None.

## Ethical considerations

**Protection of people and animals.** The authors declare that no experiments were conducted on humans or animals for this research.

**Confidentiality, informed consent, and ethical approval.** The authors followed their institution's

confidentiality protocols, obtained informed consent from patients, and have the approval of the Ethics Committee. The recommendations of the SAGER guidelines were followed, in accordance with the nature of the study.

**Statement on the use of artificial intelligence.** The authors declare that they did not use any type of generative artificial intelligence for the writing of this manuscript.

## References

1. Bologna J, Schaffer J, Cerroni L. Dermatology. 4th ed. Netherlands: Elsevier, 2017.
2. Del Boz J, Crespo V, Rivas-Ruiz F, De Troya M. Tinea incognita in children: 54 cases. Mycoses. 2011;54:254-8.
3. Kokandi AA. Tinea incognita. Clin Cosmet Investig Dermatol. 2024;17:993-8.