

Acanthosis nigricans of ears: clinical and dermoscopy correlation

Acantose nigricante nos pavilhões auriculares: correlação clínica e dermatoscópica

Sandra Arora* and Sanjeev B. Gupta

Department of Dermatology, Venereology, Leprosy, Dr. D. Y. Patil Medical College, Hospital and Research Centre, Sant Tukaram Nagar, Pimpri, Pune, Maharashtra, India

Acanthosis nigricans is a dermatological condition characterized by the presence of dark, thick, velvety, bilaterally symmetrical plaques on the skin, primarily occurring in body folds, such as neck, armpits, and groin¹, as seen in a 32-year-old obese, diabetic, male who complained of darkness over the bilateral ear lobules for 2 months (Fig. 1). Dermoscopy revealed the presence of linear crista cutis, sulcus cutis with scattered black or dark brown dots, papillary projections, and crypts (Fig. 2). Upon investigating the patient had a high body mass index, high fasting insulin levels, and S. HbA1c. Vitamin D₃ and Vitamin B12 were reduced along with a deranged lipid profile. Thyroid (72.1 µU/ml - normal 2.6-24.9 µU/ml) function tests were within normal limits. Clinical examination and a simple non-invasive bedside test, such as dermoscopy, led to a diagnosis of acanthosis nigricans. Treatment² included weight reduction through lifestyle modifications including dietary changes and regular physical activity, topical application of glycolic acid and urea-based cream over dark areas, regular use of sunscreen twice daily, Glycolic Acid 35% peel over neck once monthly, Vitamin D₃ and Vitamin B12 supplements, and Metformin 750 mg once a day.

To conclude, this case is different as the patient has acanthosis on an unusual site such as lobules of both ears and it was associated with insulin resistance, diabetes, obesity, dyslipidemia, and Vitamin D₃ and Vitamin B12 deficiency. Therefore, in rare site

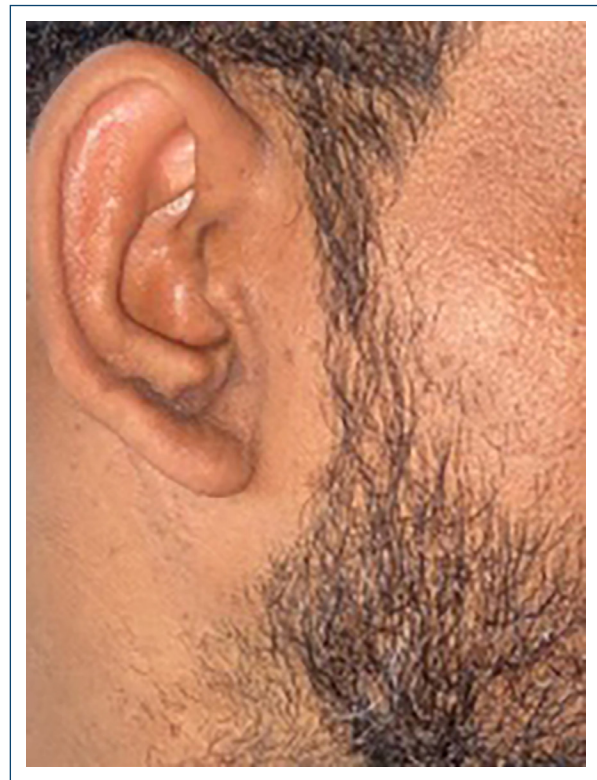


Figure 1. Thick, hyperpigmented, velvety plaque on right ear lobe.

presentation, a high index of suspicion should arise and an extensive workup is recommended as it may be associated with metabolic syndrome.

***Correspondence:**

Sandra Arora

E-mail: sandrasweet23@gmail.com

2795-501X / © 2025 Portuguese Society of Dermatology and Venereology. Published by Permanyer. This is an open access article under the CC BY-NC-ND license (<http://creativecommons.org/licenses/by-nc-nd/4.0/>).

Received: 25-02-2025

Accepted: 19-03-2025

DOI: 10.24875/PJDV.25000012

Available online: 16-07-2025

Port J Dermatol and Venereol. (ahead of print)

www.portuguesejournalofdermatology.com

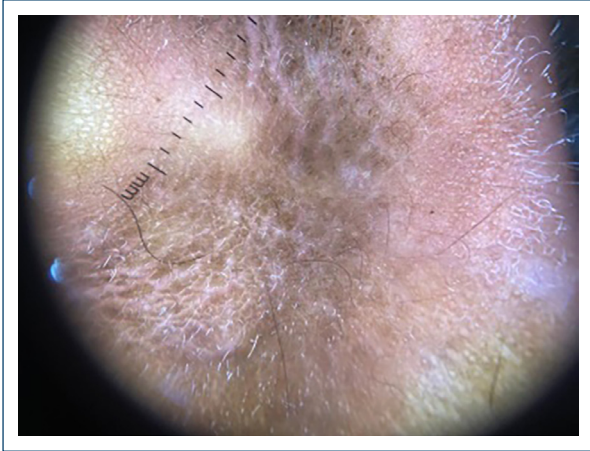


Figure 2. Polarized dermoscopy, $\times 200$ magnification, linear crista cutis, sulcus cutis with scattered black or dark brown dots, papillary projections, and crypts.

Funding

None.

Conflicts of interest

None.

Ethical considerations

Protection of humans and animals. The authors declare that no experiments involving humans or animals were conducted for this research.

Confidentiality, informed consent, and ethical approval. The authors have followed their institution's confidentiality protocols, obtained informed consent from patients, and received approval from the Ethics Committee. The SAGER guidelines were followed according to the nature of the study.

Declaration on the use of artificial intelligence. The authors declare that no generative artificial intelligence was used in the writing of this manuscript.

References

1. Tyebkhan G, Velaskar S, Yadav P, Phiske M, Shah D. An Indian expert group review of acanthosis nigricans with recommendations for early detection and timely management. *J Assoc Physicians India.* 2024 Jun 1;72(6):74-84.
2. Shah VH, Rambhia KD, Mukhi JI, Singh RP, Kaswan P. Clinico-investigative study of facial acanthosis nigricans. *Indian Dermatology Online Journal.* 2022 Mar 1;13(2):221-8.