

# An atypical presentation of hand-foot-mouth disease

## Uma apresentação atípica da doença mãos-pés-boca

Francisca Manoel<sup>1,2\*</sup> , Beatriz Sá<sup>1,3</sup> , Marta Pelicano<sup>1,4</sup> , Rui Bajanca<sup>1</sup>, and Cristina Amaro<sup>1</sup>

<sup>1</sup>Serviço de Dermatologia, Hospital de Egas Moniz, Unidade Local de Saúde de Lisboa Ocidental, Lisbon; <sup>2</sup>Serviço de Pediatria, Hospital Espírito Santo de Évora, Unidade Local de Saúde do Alentejo Central, Évora; <sup>3</sup>Serviço de Pediatria, Hospital de Santo André, Unidade Local de Saúde da Região de Leiria, Leiria; <sup>4</sup>Serviço de Pediatria, Hospital São Francisco Xavier, Unidade Local de Saúde de Lisboa Ocidental, Lisbon. Portugal

Hand-foot-mouth disease (HFMD) is an acute infectious disease caused by enteroviruses, characterized by enanthem and maculopapular and/or vesicular cutaneous rash affecting the hands, feet, and perioral and perineal regions<sup>1</sup>. Less commonly, atypical HFMD can occur with an exuberant widespread rash, increasingly associated with coxsackievirus A6<sup>2-4</sup>.

A healthy 11-month-old boy, with an epidemiological context of conjunctivitis at kindergarten, presented to the pediatric emergency department with a 3-day history of fever and 1-week history of enanthem and pruritic papulovesicular rash in perioral region, scalp, limbs, hands, and feet, with plaques and tense bullae on the thighs, extensor surfaces, and hands and feet, involving fingers (Fig. 1A-C). Nasopharyngeal swab was positive for enterovirus/rhinovirus. Impetiginized viral rash and eczema herpeticum were considered and the patient started on antibiotic and antiviral medication.

The exuberance of the rash prompted a dermatology consultation. Considering the clinical presentation and laboratory findings, and after a typical skin biopsy (Fig. 2), the diagnosis of HFMD was made. The antibiotic and antiviral medication was discontinued, and the infant was discharged after 4 days. 2 weeks later, the skin lesions had resolved, but the child developed onychomadesis.

While enterovirus infections in infants can vary in severity, coxsackie A6 is often linked to characteristic lesions, including those on the hand and feet and onychomadesis<sup>5</sup>, suggesting this patient may have been infected by this serotype, although it was not possible to confirm it.

This atypical presentation that delayed diagnosis, highlighting the need for clinicians to be aware of exuberant unusual clinical presentations and potential serious complications of HFMD, even in pediatric patients<sup>4</sup>.

**\*Correspondence:**

Francisca Manoel

E-mail: mfranciscamanoel@gmail.com

2795-501X / © 2025 Portuguese Society of Dermatology and Venereology. Published by Permanyer. This is an open access article under the CC BY-NC-ND license (<http://creativecommons.org/licenses/by-nc-nd/4.0/>).

**Received:** 19-03-2025

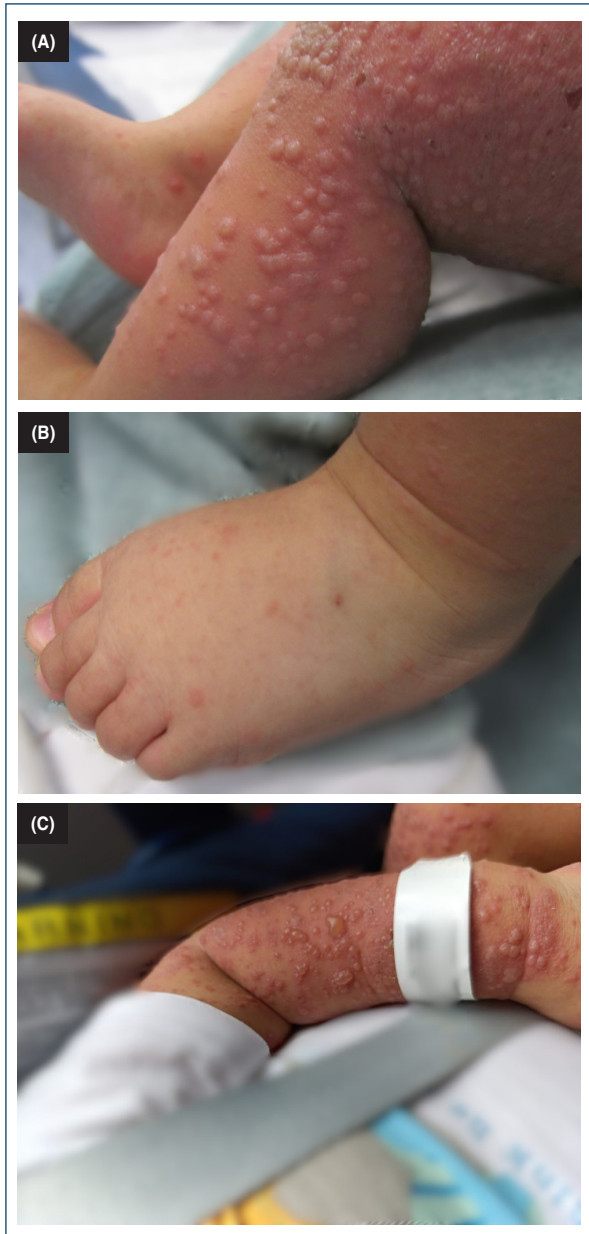**Accepted:** 19-05-2025

DOI: 10.24875/PJDV.25000019

Available online: 20-01-2026

Port J Dermatol and Venereol. (ahead of print)

[www.portuguesejournalofdermatology.com](http://www.portuguesejournalofdermatology.com)



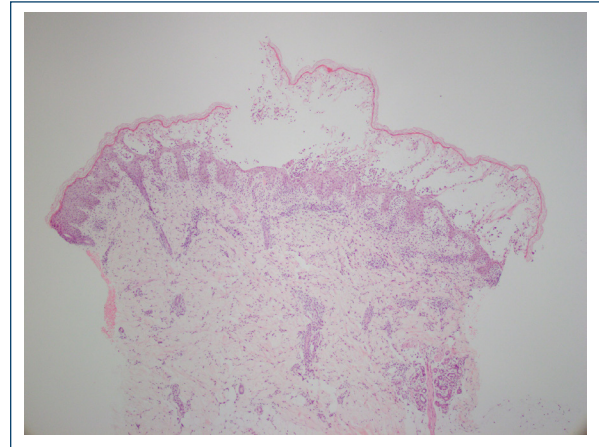
**Figure 1.** **A:** papulovesicular rash. **B:** hands and feet rash, involving the dorsum of feet and fingers. **C:** tense bubble in the extensor surface of the left arm.

### Funding

None.

### Conflicts of interest

None.



**Figure 2.** Skin biopsy, stained with hematoxylin-eosin, showed an intraepidermal vesicle with marked intracellular edema, focal superficial epidermal necrosis, with a mostly neutrophilic infiltrate, and a perivascular and interstitial mixed inflammatory infiltrate in the superficial dermis

### Ethical considerations

**Protection of humans and animals.** The authors declare that no experiments involving humans or animals were conducted for this research.

**Confidentiality, informed consent, and ethical approval.** The authors have followed their institution's confidentiality protocols, obtained informed consent from patients, and received approval from the Ethics Committee. The SAGER guidelines were followed according to the nature of the study.

**Declaration on the use of artificial intelligence.** The authors declare that no generative artificial intelligence was used in the writing of this manuscript.

### References

1. Cox B, Levent F. Hand, foot, and mouth disease. *JAMA*. 2018;320:2492.
2. Yasui Y, Makino T, Hanaoka N, Owa K, Horikoshi A, Tanaka A, et al. A case of atypical hand-foot-and-mouth disease caused by coxsackievirus A6: differential diagnosis from varicella in a pediatric intensive care unit. *Jpn J Infect Dis*. 2013;66:564-6.
3. Sinclair C, Gaunt E, Simmonds P, Broomfield D, Nwafor N, Wellington L, et al. Atypical hand, foot, and mouth disease associated with coxsackievirus A6 infection, Edinburgh, United Kingdom, January to February 2014. *Euro Surveill*. 2014;19:20745.
4. Fölster-Holst R. Classical hand, foot and mouth disease replaced by atypical hand, foot and mouth disease. *Acta Derm Venereol*. 2018;98:303.
5. Flett K, Youngster I, Huang J, McAdam A, Sandora TJ, Rennick M, et al. Hand, foot, and mouth disease caused by coxsackievirus A6. *Emerg Infect Dis*. 2012;18:1702-4.