

Apocrine hidrocystoma of the breast: a case report of unusual clinical and dermoscopic findings

Hidrocistoma apócrino mamário: um caso com aspetos clínicos e dermatoscópicos invulgares

Ma. Cristina Fialho^{1*}, Emanuel Marques^{1,2}, Monika Arenbergerová^{3,4}, Petr Arenberger^{3,4}, Zoltán Paluch^{5,6}, and Marek Pásek^{3,4}

¹Department of Dermatology and Venereology, Hospital de Santo António dos Capuchos, Unidade Local de Saúde de São José, Lisbon, Portugal; ²Department of Dermatology and Venereology, NOVA Medical School, NOVA University of Lisbon, Lisbon, Portugal; ³Department of Dermatology and Venereology, Královské Vinohrady University Hospital, Prague, Czech Republic; ⁴Department of Dermatology and Venereology, Third Faculty of Medicine, Charles University, Prague, Czech Republic; ⁵Department of Clinical Pharmacology and Pharmacy, General University Hospital, Prague, Czech Republic; ⁶Department of Clinical Pharmacology and Pharmacy, General University Hospital, Institute for the Care of Mother and Child, Prague, Czech Republic

A 33-year-old woman presented with a 6-month history of a gradually increasing papule on her right breast. A 17 mm red-violet, asymptomatic, relatively indurated dome-shaped nodule was identified (Fig. 1A). Dermoscopic examination (Fig. 1B) revealed a central homogeneous bluish-gray area with a few short linear-irregular vessels, an erythematous area with shiny whitish structures and a pigmented pseudo-network. Ultrasound examination revealed a cystic hypoechoic mass. Excision of the lesion was proposed, and the patient was at her 36th week (+4 days) of pregnancy on the day of the procedure. Histologic examination revealed an apocrine hidrocystoma.

Apocrine hidrocystomas are benign tumors of the apocrine sweat glands most frequently found on the head and neck¹. Few have been reported in other areas¹⁻⁴. Most grow to sizes varying from 1 to 10 mm;

there are only few reports of larger lesions². Our dermoscopic findings do not correspond to the most frequent patterns reported by Zaballos et al.¹ gray and pink homogenous areas and linear-irregular vessels were only found in 4.8% and 9.1% of reported cases; moreover, pigmented pseudo-networks have not been described¹. In the differential diagnosis, atypical dermatofibroma, pigmented basal cell carcinoma, amelanotic melanoma or other adnexal tumors should be considered, particularly when atypical dermoscopic findings are present³. We hypothesize that a pigmented pseudo-network may have been caused by irritation derived from a chronic inflammatory process. The atypical findings of our hidrocystoma enhance the need for physicians to be aware of uncommon locations and dermoscopic findings of these lesions.

*Correspondence:

Ma. Cristina Fialho
E-mail: cris.fialho.3@gmail.com

Received: 28-03-2025

Accepted: 09-04-2025
DOI: 10.24875/PJDV.25000022

Available online: 23-05-2025

Port J Dermatol and Venereol. (ahead of print)
www.portuguesejournalofdermatology.com

2795-501X / © 2025 Portuguese Society of Dermatology and Venereology. Published by Permanyer. This is an open access article under the CC BY-NC-ND license (<http://creativecommons.org/licenses/by-nc-nd/4.0/>).

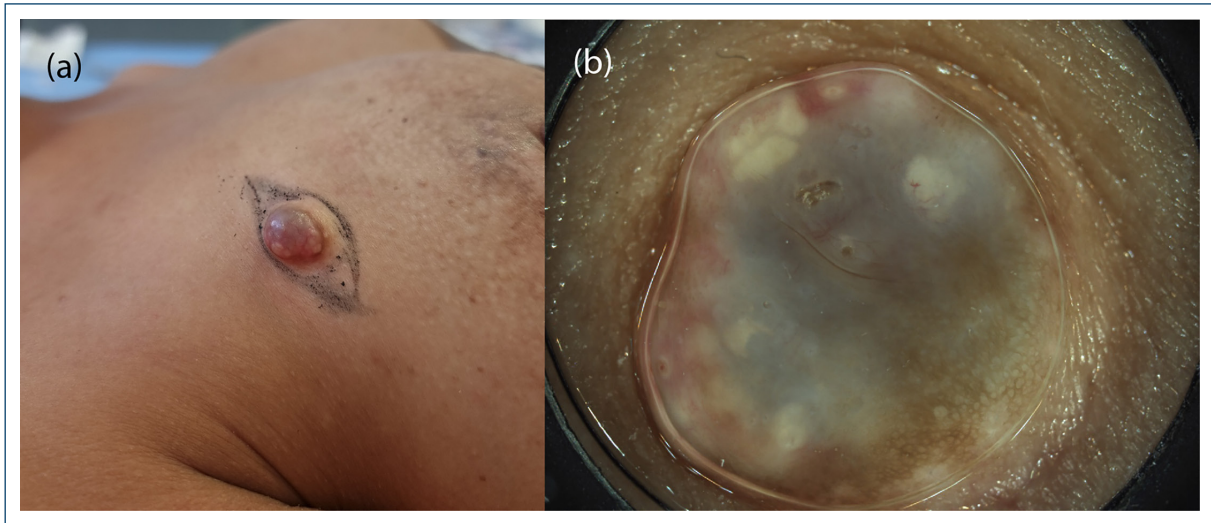


Figure 1. A: clinical picture of the dome-shaped nodule on the right breast; **B:** dermoscopy of the apocrine hidrocystoma in vivo before excision.

Funding

None.

Conflicts of interest

None.

Ethical considerations

Protection of humans and animals. The authors declare that no experiments involving humans or animals were conducted for this research.

Confidentiality, informed consent, and ethical approval. The authors have followed their institution's confidentiality protocols, obtained informed consent from

patients, and received approval from the Ethics Committee. The SAGER guidelines were followed according to the nature of the study.

Declaration on the use of artificial intelligence.

The authors declare that no generative artificial intelligence was used in the writing of this manuscript.

References

1. Zaballos P, Bañuls J, Medina C, Salsench E, Serrano P, Guionnet N. Dermoscopy of apocrine hidrocystomas: a morphological study. *J Eur Acad Dermatol Venereol.* 2014;28:378-81.
2. May C, Chang O, Compton N. A giant apocrine hidrocystoma of the trunk. *Dermatol Online J.* 2017;23:13030/qt8bm3r2h4.
3. Cieza-Díaz DE, Avilés-Izquierdo JA, Ciudad-Blanco C, Parra-Blanco V. Dermoscopy of apocrine tumors: report of 4 cases. *Actas Dermosifiliogr.* 2013;104:826-8.
4. Samplaski MK, Somani N, Palmer JS. Apocrine hidrocystoma on glans penis of a child. *Urology.* 2009;73:800-1.