

Perforating necrobiosis lipoidica in an old surgical scar

Necrobiose lipoidica perfurante sobre antiga cicatriz cirúrgica

Maria Relvas^{a,*}, Francisca Morgado, José C. Cardoso, and Margarida Gonçalo*

Dermatology Department, Coimbra University Hospital Center, Coimbra, Portugal

^aORCID: 0000-0002-2639-7494

Abstract

Necrobiosis lipoidica (NL) is an idiopathic granulomatous disease, frequently associated with diabetes mellitus. Histologically, it is characterized by palisaded granulomas involving the deep dermis, but the epidermis is usually spared. We describe a case of perforating NL (PNL), a rare variant of NL, occurring in an atypical location—an old surgical scar on the elbow—in a 70-year-old, non-diabetic, female patient. Histopathological examination of a skin biopsy demonstrated a palisading granulomatous infiltrate involving the full dermis, with an area of epidermal invagination and transepithelial elimination of necrotic material. Clinically, the particularity of PNL is the presence of multiple hyperkeratotic plugs or plaques, within a typical lesion of NL, which correspond to the necrobiotic material being eliminated through the epidermis. Treatment of PNL is still challenging, mainly due to its rarity. Our patient was treated with clobetasol propionate ointment 0.05% one daily, with significant improvement.

Keywords: Cicatrix/complications. Necrobiosis lipoidica. Surgical wound.

Resumo

A necrobiose lipoidica é uma doença granulomatosa idiopática, frequentemente associada a diabetes *mellitus*. Histologicamente, caracteriza-se por granulomas em paliçada que envolvem a derme profunda, estando a epiderme geralmente poupada. Descrevemos o caso de uma variante rara de necrobiose lipoidica, denominada necrobiose lipoidica perfurante, numa localização atípica - uma antiga cicatriz cirúrgica no cotovelo - numa doente de 70 anos, não diabética. O exame histopatológico demonstrou infiltrado granulomatoso em paliçada, ocupando toda a espessura da derme, com uma área de invaginação epidérmica e eliminação transepitelial de material necrótico. Clinicamente, a necrobiose lipoidica perfurante distingue-se pela presença de múltiplos rolhões ou pequenas placas hiperqueratóticas, sobrepostas a uma lesão típica de necrobiose lipoidica, correspondendo ao material necrótico em eliminação pela epiderme. Devido à sua raridade, o tratamento da necrobiose lipoidica perfurante é ainda desafiante. A nossa doente foi medicada com pomada de propionato de clobetasol 0,05% uma vez por dia, demonstrando melhora significativa.

Palavras-chave: Cicatriz/complicações. Ferida cirúrgica. Necrobiose lipoidica.

Corresponding author:

*Maria Relvas

E-mail: mariavrelvas@gmail.com

2797-5001 / © 2021 Portuguese Society of Dermatology and Venereology. Published by Permanyer. This is an open access article under the CC BY-NC-ND license (<http://creativecommons.org/licenses/by-nc-nd/4.0/>).

Received: 29-05-2021

Accepted: 14-08-2021

DOI: 10.24875/PJD.M22000008

Available online: 16-05-2022

Port J Dermatol and Venereol. 2022;80(1):47-50

www.portuguesejournalofdermatology.com

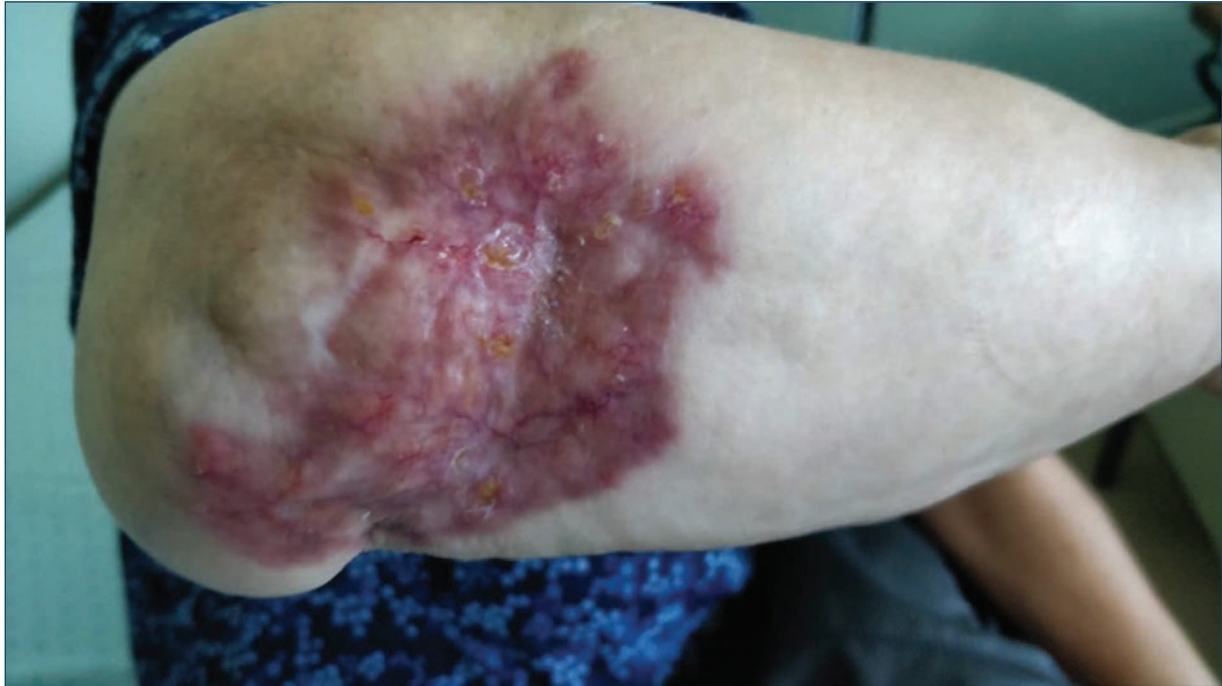

Figure 1. An erythematous, infiltrated plaque measuring 10x8 cm, with an atrophic yellowish, telangiectatic center at the location of a previous surgical scar on the right elbow.

Introduction

Necrobiosis lipoidica (NL) is an idiopathic granulomatous disease classically associated with diabetes mellitus, although patients with normal glucose metabolism may also be affected. Other related conditions include sarcoidosis, monoclonal gammopathy, and auto-immune diseases¹. It presents as asymptomatic, well-demarcated plaques, with erythematous, active borders and a yellow-brown, atrophic and telangiectatic center. It occurs most frequently located on the bilateral lower extremities, but the face, trunk and upper extremities may also be involved. Histologically, NL belongs to the group of palisaded granulomas, which are characterized by tiers of collagen degeneration surrounded by histiocytes¹.

Case report

A 70-year-old female presented with a 3-year history of an enlarging asymptomatic lesion on the right elbow, surrounding a scar from two orthopedic surgeries performed 10 years before, due to recurrent bursitis. Physical examination revealed a well-demarcated 10 × 8 cm infiltrated and atrophic erythematous plaque with yellowish areas, telangiectasia (Fig. 1) and multiple 2-5 mm hyperkeratotic plugs that were not easily detached (Fig. 2). Laboratory workup, including complete blood

count, serum chemistry, fasting glucose levels, serum angiotensin converting enzyme, antinuclear antibodies, complement levels and C-reactive protein were normal. The patient was under long-term treatment with atorvastatin for hyperlipidemia but was otherwise healthy.

Histopathology showed a palisading granulomatous infiltrate involving the full dermal thickness (Fig. 3), predominantly composed of histiocytes and multinucleated giant cells, mostly of the Langhans-type, surrounding extensive areas of collagen degeneration with karyorrhexis (Fig. 4). At the periphery, there were several foci of an inflammatory infiltrate consisting of lymphocytes and plasma cells. In addition, there was an area of epidermal invagination with transepithelial elimination of the involved necrotic material. Staining with Periodic acid-Schiff and Ziehl-Nielsen showed no microorganisms. Clinical and histopathological data were consistent with the diagnosis of perforating NL (PNL).

The lesion improved significantly within the next weeks with clobetasol propionate ointment 0.05% once daily.

Discussion

This case represents a rare example of PNL in a non-diabetic patient, occurring in an atypical location, an old surgical scar. Only about 15 cases of PNL have

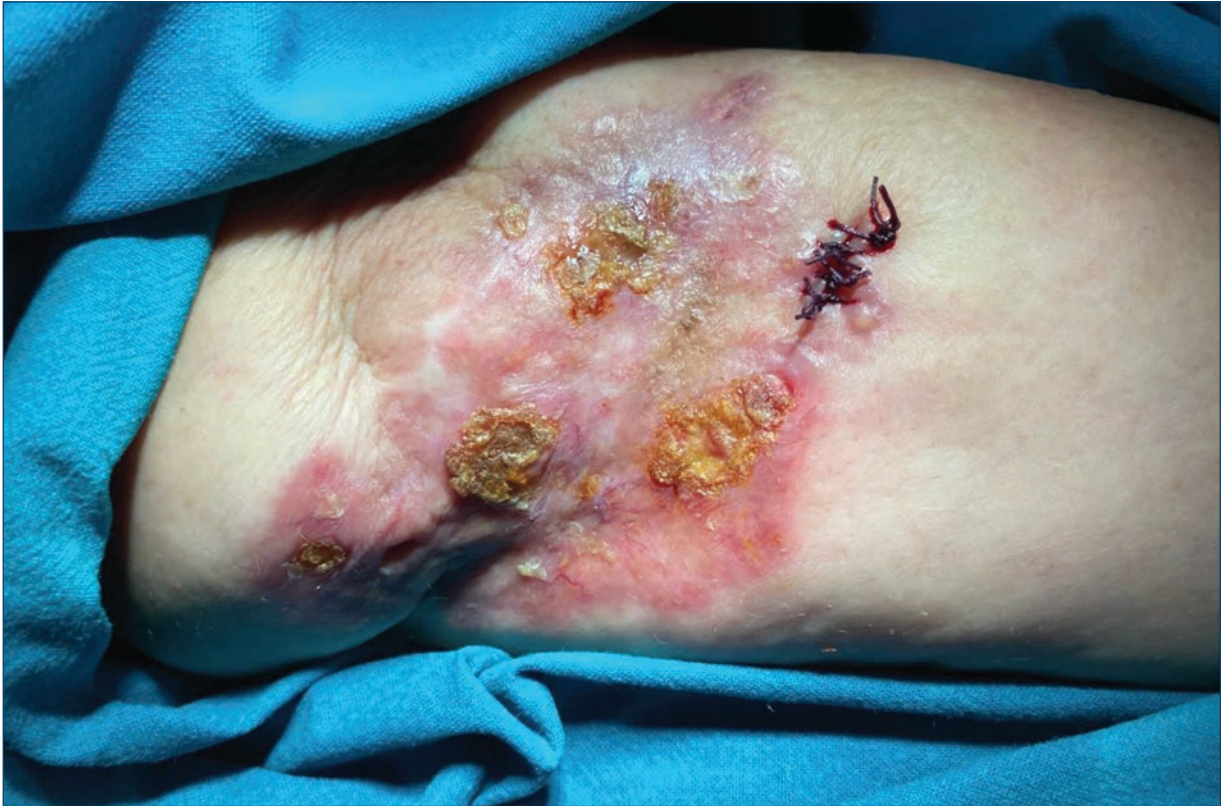

Figure 2. Multiple 2-5 mm hyperkeratotic plugs over the erythematous and infiltrated plaque.

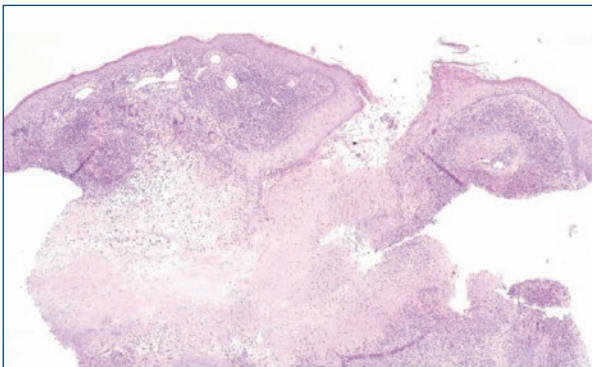


Figure 3. Palisading granulomatous infiltrate surrounding an extensive area of collagen degeneration, with transepithelial elimination of the necrotic material (hematoxylin & eosin $\times 40$).

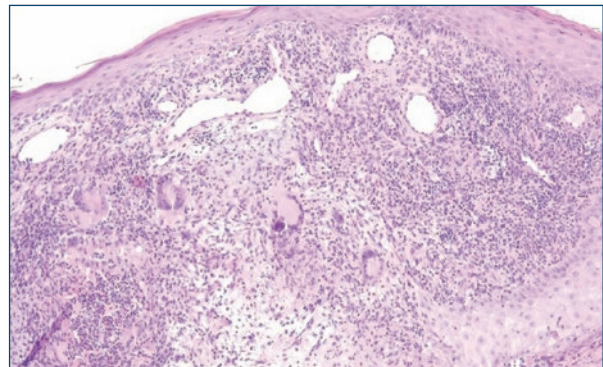


Figure 4. Inflammatory infiltrate composed predominantly of histiocytes and Langhans-type multinucleated giant cells, with lymphocytes and plasma cells at the periphery, and some neutrophils with karyorrhexis (hematoxylin & eosin $\times 100$).

been reported, mostly in diabetic, middle-aged women, like the non-perforating variant of NL¹. The particularity of PNL is the presence of multiple hyperkeratotic plugs or plaques within a typical lesion of NL, which on removal leave a residual depression². They correspond to necrobiotic material that is being eliminated through the epidermis and follicular units. Main locations of PNL are similar to the classic NL. Two cases

of PNL with disseminated lesions have been described, although none with a single lesion in the upper limbs². As in NL, epidermoid carcinoma has been reported in PNL lesions³, but in our patient, there were no signs of malignant transformation after 3 years of follow-up.

In NL, palisading granulomas and infiltrating histiocytes surround areas of collagen degeneration (necrobiosis) and involve the deep dermis, sometimes extending to the

subcutaneous tissue, but the epidermis is usually spared¹. In PNL, there is an invagination of the epidermis and transepidermal elimination of the necrotic material.

PNL belongs to the group of acquired perforating dermatosis characterized by transepidermal elimination of materials such as collagen, elastic fibers, and keratin⁴. The exact pathogenesis of perforating dermatosis remains unclear, although patients frequently demonstrate the Koebner phenomenon⁴, in this case eventually related to the previous surgical scar. NL has already been reported on surgical scars¹, but this is the first report of PNL occurring on an old and previous stable surgical scar.

Treatment of both NL and PNL is still challenging, in part because of their rarity. Local therapies, including intralesional and topical corticosteroids, tacrolimus, and tretinoin, can improve the lesions. In severe or refractory cases, systemic therapies such as corticosteroids, cyclosporine, mycophenolate mofetil or clofazimine, may be beneficial. More recently, a case of PNL was successfully treated with adalimumab⁵.

Funding

This work has not received any contribution, grant or scholarship.

Conflicts of interest

The authors have no conflicts of interest to declare.

Ethical disclosures

Protection of human and animal subjects.

The authors declare that the procedures followed were in accordance with the regulations of the relevant clinical research ethics committee and with those of the Code of Ethics of the World Medical Association (Declaration of Helsinki).

Confidentiality of data. The authors declare that they have followed the protocols of their work center on the publication of patient data.

Right to privacy and informed consent. The authors have obtained the written informed consent of the patients or subjects mentioned in the article. The corresponding author is in possession of this document.

References

1. Sibbald C, Reid S, Dermatol Clin. Alavi A. Necrobiosis lipoidica. *Dermatol Clin.* 2015;33:343–60.
2. Gori N, Di Stefani A, De Luca EV, Peris K. A case of disseminated perforating necrobiosis lipoidica. *Clin Case Rep.* 2020;8:808–10.
3. Vanhooiteghem O, André J, de la Brassinne M. Epidermoid carcinoma and perforating necrobiosis lipoidica: a rare association. *J Eur Acad Dermatol Venereol.* 2005;19:756–8.
4. García-Malínis AJ, Del Valle Sánchez E, Sánchez-Salas MP, Del Prado E, Coscojuela C, Gilaberte Y. Acquired perforating dermatosis: clinicopathological study of 31 cases, emphasizing pathogenesis and treatment. *J Eur Acad Dermatol Venereol.* 2017;31:1757–63.
5. Nunes de Mattos AB, Brummer CF, Funchal GD, Nunes DH. Perforating necrobiosis lipoidica: good response to adalimumab. *An Bras Dermatol.* 2019;94:769–71.