

Hair-follicle transplant as chronic skin ulcer treatment

Enxerto de folículos pilosos como tratamento de ulceração crónica

Leandro Silva^{1,a,*} and Rui Oliveira Soares²

¹Dermatology Department, Hospital de Egas Moniz, Centro Hospitalar Lisboa Ocidental; ²Dermatology Center, CUF Descobertas Hospital, Lisbon, Portugal

^aORCID: 0000-0001-7804-3092

Abstract

Chronic skin ulcers treatment is a common challenge in clinical dermatology practice. In recent years, hair-follicles transplantation emerged as an effective chronic skin ulcer treatment. The healing improvement is probably due to the action of follicle stem cells. We present a case of a chronic skin ulcer due to livedoid vasculopathy that fully healed 2 months after hair-follicle implantation into the wound bed.

Keywords: Hair follicle. Transplantation. Skin transplantation. Skin ulcer.

Resumo

O tratamento da ulceração cutânea crónica é um desafio comum da prática diária da dermatologia. Nos últimos anos, o enxerto de folículos pilosos mostrou ser eficaz no tratamento das úlceras cutâneas crónicas. A melhora da cicatrização deve-se, provavelmente, à ação das células estaminais pluripotentes existentes nos folículos pilosos. Neste artigo reportamos um caso de úlcera cutânea crónica que resolveu totalmente dois meses após o implante de folículos pilosos no leito da úlcera.

Palavras-chave: Folículo piloso. Transplantação. Transplante de pele. Úlcera de pele.

Introduction

Chronic skin ulcers may represent a therapeutic challenge. Multiple options ranging from wound dressings, compressive therapy, and surgical procedures may promote ulcer healing^{1,2}.

Hair-follicle derived cells have the potential to differentiate and promote wound healing^{3,4}. It has been shown that reepithelization initiates in the hair-follicle and spreads around⁵.

It is hypothesized that hair-follicles are a reservoir of progenitor cell populations that when stimulated by cytokines, such as transforming growth factor beta 1 and vascular endothelial growth factor, can differentiate into the main skin compartments⁶.

Transplantation of scalp hair-follicles into chronic wounds, using common hair transplantation technique, has proven successful in promoting ulcer healing^{2,3}.

Corresponding author:

*Leandro Silva

E-mail: leandrofilipe@hotmail.com

2797-5001 / © 2021 Portuguese Society of Dermatology and Venereology. Published by Permanyer. This is an open access article under the CC BY-NC-ND license (<http://creativecommons.org/licenses/by-nc-nd/4.0/>).

Received: 21-09-2021

Accepted: 18-12-2021

DOI: 10.24875/PJD.M22000013

Available online: 16-05-2022

Port J Dermatol and Venereol. 2022;80(1):68-70

www.portuguesejournalofdermatology.com

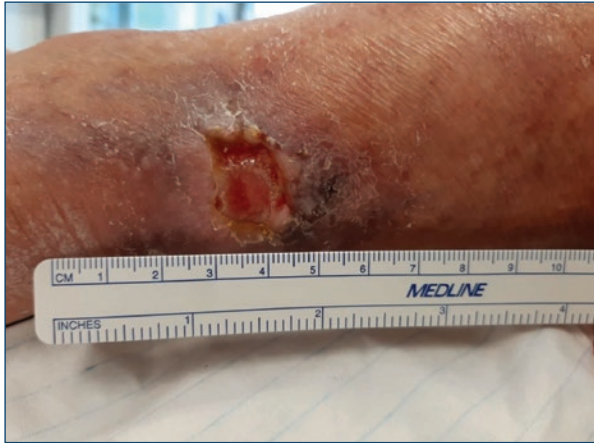

Figure 1. Chronic non-healing skin ulcer located on the right leg, measuring 2 × 1.5 cm.

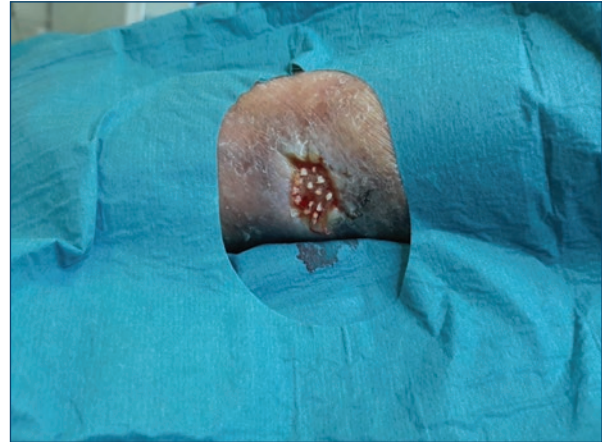


Figure 3. Insertion of each follicular unit on the wound bed.

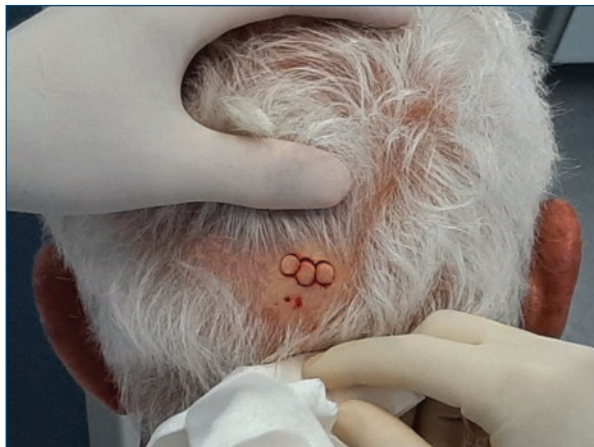

Figure 2. Collection of three 6 mm scalp punch biopsies.

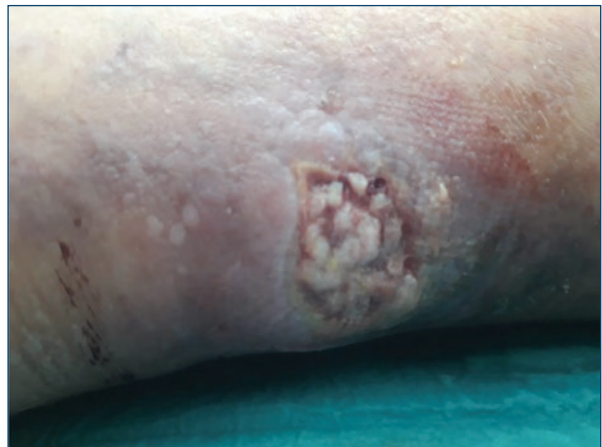

Figure 4. One week after the procedure, 50% of wound was covered by the grafts.

Case report

We observed a 77-year-old male patient with medical history of hypertension, admitted to the Dermatology Department due to a chronic ulcer located on the posterior side of the right leg that persisted for the past 6 months in spite of conventional treatment (compression bandage and hydrocolloid dressing). We observed an irregular 4 mm deep ulcer, measuring 2 × 1.5 cm, with mild yellowish exudate in the wound bed, surrounded by hard consistent fibrous tissue (Fig. 1). A Doppler ultrasound excluded arterial disease.

Due to conventional treatment failure, we decided to transplant hair-follicle grafts from the patient's scalp into the ulcer.

Initially, under local anesthesia, we collected skin from occipital scalp using a 6 mm punch (Fig. 2) and removed the adipose subcutaneous tissue in excess.

After this, the hair grafts were immersed in physiologic saline solution and divided in follicular units which were inserted into the recipient wound bed with a 19-gauge needle (Fig. 3). The area was covered with a petrolatum impregnated gauze dressing and a mild compression bandage was applied.

One week after treatment the grafts occupied more than 50% of the wound (Fig. 4). Two months after the procedure the wound bed was almost fully healed (Fig. 5).

Discussion

Punch grafting of hair follicles is a surgical option that should be considered in skin ulcers that are refractory to treatment. Hair follicle stem cells can differentiate into keratinocytes and provide biologic material to replenish

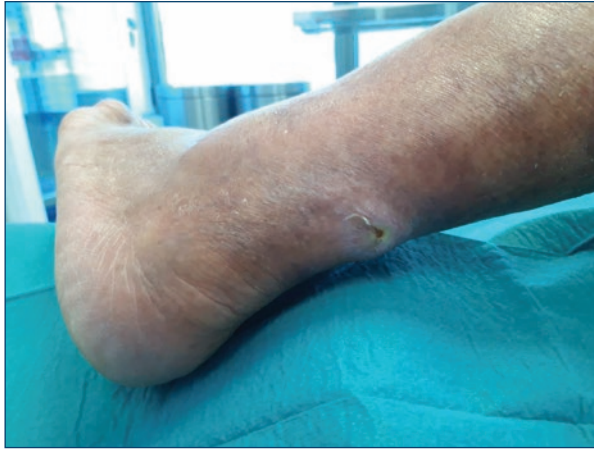

Figure 5. Two months after the procedure the wound bed was almost fully healed.

the skin. The scalp constitutes an anatomical area suitable for harvesting skin grafts, given its accessibility, low risk of infection, fast healing, negligible cicatricial remnants, and stem cells availability⁷. Besides, when comparing donor areas of the scalp and abdominal skin, the former has demonstrated a faster and higher regenerative potential⁴. This is due to the higher number of hair follicles, most in anagen phase, providing elements for a faster growth rate². The growth rate of hair follicles in the wound bed seems to be different when compared with follicles implanted into the scalp for hair transplantation⁸. It is not known why this happens, but it has been suggested that this may reflect the microenvironment of the injured wound bed, that prioritizes the regeneration of the wound healing instead of hair growth⁹. We report this case to support scalp punch grafting as a therapeutic option for chronic skin ulcers. This is a simple procedure that does not require expensive equipment or general anesthesia and can be performed in a small surgery room by a dermatologist.

Funding

This work has not received any contribution, grant or scholarship.

Conflicts of interest

The authors have no conflicts of interest to declare.

Ethical disclosures

Protection of people and animals. The authors declare that for this investigation no experiments were carried out on humans and/or animals.

Data confidentiality. The authors declare that they have followed the protocols of their work center regarding the publication of patient data.

Right to privacy and written consent. The authors declare that they have received written consent from the patients and/or subjects mentioned in the article. The corresponding author must be in possession of this document.

References

1. Han G, Ceilley R. Chronic wound healing: a review of current management and treatments. *Adv Ther.* 2017;34:599–610.
2. Martínez ML, EscarioTravesedo E, Acosta FJ. Healing of recalcitrant chronic venous leg ulcers by punch graftsharvested from the scalp. *Dermatol Surg.* 2015;41:1085–7.
3. Jimenez-Acosta F, Ponce-Rodriguez I. Follicular unit extraction for hair transplantation: an update. *Actas Dermosifiliogr.* 2017;108:532–7.
4. Martínez ML, Escario E, Poblet E, Sánchez D, Buchón FF, Izeta A, et al. Hair follicle-containing punch grafts accelerate chronic ulcer healing: a randomized controlled trial. *J Am Acad Dermatol.* 2016;75:1007–14.
5. Bishop B. Regeneration after experimental removal of skin in man. *Am J Anat.* 1945;76:153–81.
6. Alam M, Cooley J, Plotczyk M, Martínez-Martín MS, Izeta A, Paus R, et al. Distinct patterns of hair graft survival after transplantation into 2 nonhealing ulcers: is location everything? *Dermatol Surg* 2019;45:557–65.
7. Weyandt GH, Bauer B, Berens N, Hamm H, Broecker EB. Splitskin grafting from the scalp: the hidden advantage. *Dermatol Surg.* 2009;35:1873–9.
8. Liu JQ, Zhao KB, Feng ZH, Qi FZ. Hair follicle units promote re-epithelialization in chronic cutaneous wounds: a clinical case series study. *Exp Ther Med.* 2015;10:25–30.
9. Jahoda CAB, Reynolds AJ. Hair follicle dermal sheath cells: unsung participants in wound healing. *Lancet.* 2001;358:1445–8.