

Recurrent acral ulcerations associated with DNA methyltransferase 1-complex disorder

Ulcerações acrais recorrentes secundárias a doença do complexo-DNMT1

Diogo Cerejeira^{1,a,*}, Frederico Bonito¹, Cristina Ione², Henriqueta Cunha¹, and Pedro Pereira²

¹Dermatology Department; ²Neurology Department. Hospital Garcia de Orta, EPE, Almada, Portugal
^aORCID: 0000-0001-8586-6580

Abstract

DNA methyltransferase 1, encoded by *DNMT* gene, is a crucial DNA methyltransferase with essential roles in transcription regulation, gene imprinting, and cell differentiation. Dysfunction of this group of enzymes can lead to a variety of neurologically predominant clinical symptoms, including a stereotypic triad of sensory predominant neuropathy, sensorineural hearing loss, and cognitive decline. Herein, we report the case of a Portuguese patient who presented with recurrent acral ulcerations due to hypoalgesia and hypoaesthesia, secondary to a novel heterozygous mutation [c.1718T>G (p.Val573Gly)] in DNA methyltransferase 1 gene.

Keywords: DNA (Cytosine-5)—Methyltransferase 1/genetics. Skin ulcer. Etiology.

Resumo

A DNA metiltransferase 1, codificada pelo gene *DNMT*, é uma DNA metiltransferase crucial na regulação da transcrição, impressão genómica e diferenciação celular. A disfunção desse grupo de enzimas pode conduzir a uma grande variedade de sintomas clínicos de predomínio neurológico, nomeadamente uma tríade característica composta por neuropatia sensitiva, surdez neurossensorial e declínio cognitivo. Neste trabalho, relatamos o caso de um doente de nacionalidade portuguesa, que foi observado em consulta por ulcerações acrais recorrentes devido a hypoalgesia e hipoestesia, secundárias a uma nova mutação heterozigótica [c.1718T> G (p.Val573Gly)] no gene *DNMT1*.

Palavras-chave: DNA (Citosina-5)—Metiltransferase 1/genética. Úlcera de Pele. Etiologia.

Introduction

DNA methyltransferase 1 (*DNMT1*), encoded by the *DNMT1* gene, is one of the key enzymes responsible for maintaining methylation during chromosome replication and DNA repair^{1,2}. Mutations in *DNMT1* have

been associated with two autosomal dominant neurodegenerative disorders, in particular (1) hereditary sensory autonomic neuropathy with dementia and hearing loss (HSAN1E) and (2) autosomal dominant cerebral ataxia, deafness, and narcolepsy^{3,4}. Studies have shown that these diseases are often characterized by

Corresponding author:

*Diogo Cerejeira

E-mail: diogo_cerejeira@hotmail.com

2797-5001 / © 2021 Portuguese Society of Dermatology and Venereology. Published by Permanyer. This is an open access article under the CC BY-NC-ND license (<http://creativecommons.org/licenses/by-nc-nd/4.0/>).

Received: 30-08-2021

Accepted: 09-10-2021

DOI: 10.24875/PJD.M22000014

Available online: 16-05-2022

Port J Dermatol and Venereol. 2022;80(1):71-74

www.portuguesejournalofdermatology.com

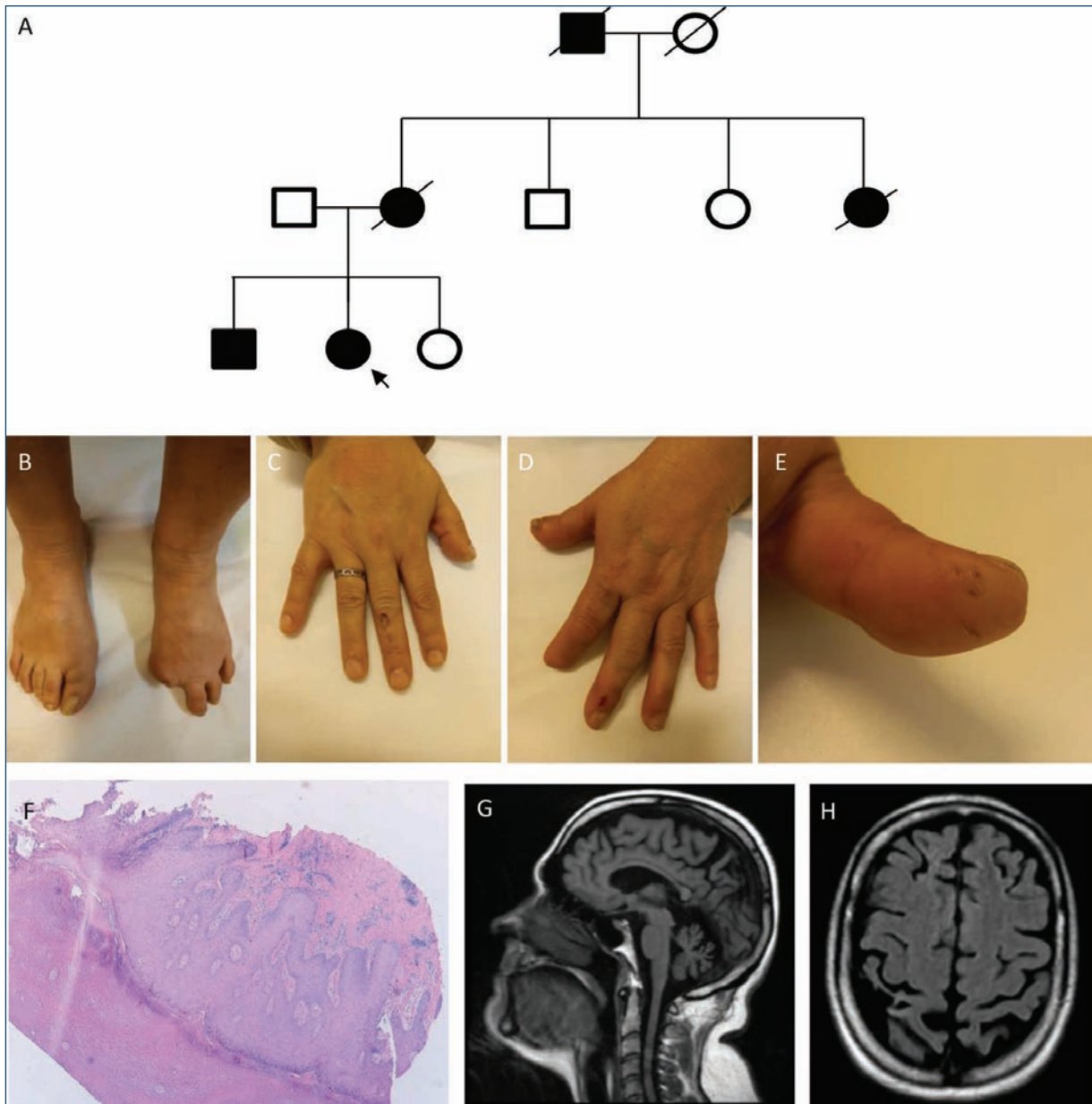


Figure 1. Pedigree and clinical photographs. **A:** family pedigree. The black arrow indicates the index case. Deceased cases are only based on the family history. **B-D:** sequelae of the amputations and thermal injuries. **E:** pitted scars resulting from the healing of previous ulcers. **F:** cutaneous biopsy (H&E $\times 40$). Hyperkeratosis and acanthosis, with a moderate lymphocytic infiltrate. **G and H:** brain magnetic resonance imaging. Sagittal T2-FLAIR sequence showed cerebellar atrophy. Coronal T2-FLAIR sequence demonstrated a diffuse cortical brain atrophy.

overlapping clinical features and should be considered as a continuum of a common neurodegenerative spectrum, leading to the proposal of the unified terminology of “DNMT1-complex disorder”⁵.

Case report

A 47-year-old Portuguese woman was referred to our department due to recurrent acral ulcerations over

the past decade. The patient reported previous debridement of multiple ulcers on her feet and hands, and she had already been submitted to the amputation of two different toes and of the distal phalanx of her left index, as a consequence of local infection and osteomyelitis. Relevant medical history included a progressive bilateral hearing loss in her early 30s and cognitive decline with memory dysfunction and behavioral symptoms such as apathy. No significant cardiovascular risk factors were

detected, except for previous smoking habits. Family history revealed that her maternal grandfather died at a young age and suffered from “foot ulcers,” her maternal aunt had acral ulcerations attributed to diabetes mellitus and her mother had a similar history of acquired hearing loss in early adulthood (Fig. 1A). Her family was non-consanguineous, and she had two siblings with unremarkable medical history.

On physical examination, it was possible to detect the sequelae of amputations, acromutilations and the presence of pitted scars resulting from ulcer healing (Fig. 1B-E). Peripheral pulses were palpable and there was no evidence of skin sclerosis, Raynaud phenomenon or livedo reticularis. On neurologic examination, cranial nerves were normal except for symmetric bilateral hearing loss. Muscle tone and strength were normal, but a generalized hyporeflexia was noticed. It was also detected a significant hypoalgesia below the knees and a loss of position and vibration sense in both feet, with a positive Romberg test. Mild cerebellar signs were present with dysmetria on finger-to-nose-test, without worsening with eyes closed.

Blood tests were unremarkable, including blood cell counting, coagulation studies, cryoglobulins, and autoimmunity screening (anti-nuclear, anti-double-stranded DNA, lupus anticoagulant, anti-cardiolipin, anti α -2 glycoprotein-I, and anti-neutrophil cytoplasmic antibodies). Serology for HIV 1/2, hepatitis B/C, and syphilis was negative. Nailfold capillaroscopy and the Doppler ultrasonography of the lower and upper limbs showed no alterations. Cutaneous biopsy revealed unspecific features, including hyperkeratosis and acanthosis, with a moderate lymphocytic infiltrate (Fig. 1F). The pure tone audiometry examination suggested moderate-to-severe bilateral sensorineural hearing loss between the frequencies of 1000 and 4000 Hz. Nerve conduction studies were consistent with a pure sensory axonal neuropathy with a distal predominance. Brain magnetic resonance imaging displayed severe diffuse cerebral and cerebellar atrophy (Figs. 1G and H). Neuropsychological testing showed executive dysfunction. Sequencing of *DNMT1* gene led to the identification of a novel heterozygous variant [c.1718T>G (p.Val573Gly)] that was not previously reported in the literature or GnomAD database and bioinformatic techniques predicted as deleterious. Segregation analysis of her father and siblings was performed and allowed the identification of the same nucleotide change in her brother, a 39-year-old man. He complained of mild deafness noted 2 years priorly, and no neurological or dermatological symptoms. His neurological examination revealed an axonal sensory

polyneuropathy and confirmed through nerve conduction studies. He did not have any dermatological lesions.

Our index patient was empirically medicated with prophylactic acetylsalicylic acid, pentoxifylline, and transdermic nitroglycerine. She was also advised to protect her hands and feet and avoid the exposure to any thermal or physical trauma. During a follow-up period of 3 years, the patient remained relatively stable and without new episodes of amputation. She developed abnormal sleep behavior with frequent vivid dreams and loud vocal sounds, which were effectively controlled with oral clonazepam, suggesting a REM sleep behavior disorder, although neurophysiological studies could not be performed.

Discussion

DNMT1-complex disorder is a rare autosomal dominant disease characterized by a predominant degeneration of sensory and autonomic neurons. To date, a total of 20 mutations have been reported, most of them located within the N-terminal region and the C-terminal region of the target sequence (TS) domain of *DNMT1* gene (exons 20 and 21)⁶. Partial deletion of the TS domain abolishes the association of *DNMT1* with heterochromatin during the G2 phase of mitosis, eliciting the formation of misfolded nucleus proteins^{5,7}. Mutant proteins are then translocated and sequestered in the cytoplasm, leading to an accumulation of cytosolic aggregates that are responsible for inducing toxic cellular stress⁵. Since the methylation process is a fundamental aspect of DNA replication and cell differentiation, it is not surprising that this disorder is commonly associated with a vast spectrum of clinical presentations. Although the predominance of neuronal dysfunction is not fully elucidated, the post-mitotic neurons and the long length of peripheral nerves seem to be particularly vulnerable to mutated protein misfolding and subsequent cellular stress⁵.

The most frequent presenting symptom is sensorineural hearing loss during the second decade of life, followed by sensory predominant neuropathy and its related complications (ulcerations and arthropathy)^{5,8}. On disease progression, nearly all patients develop cognitive decline, ranging from overt dementia to milder cognitive deficits^{5,8}. Collectively, sensory predominant neuropathy, sensorineural hearing loss, and cognitive decline compose the stereotypic clinical triad of *DNMT1* complex disorder⁶.

Other variable features, that can present at different ages, include cerebellar ataxia, narcolepsy/cataplexy,

auditory and/or visual hallucinations, optic atrophy, myoclonic seizures, renal failure, parasomnias, and sudden personality changes^{5,6}. Although there is no specific treatment currently available for this disorder, its marked morbidity and reduced life expectancy, underscore the importance of a prompt diagnosis, and an early institution of the best supportive care. However, due to the high variability of the initial clinical symptoms, these patients are frequently seen by different specialties that are often unfamiliar with this extremely rare condition⁵.

Conclusion

The aim of this report is to aid clinicians to better recognize and diagnose *DNMT1*-complex disorder and to describe a novel heterozygous possibly pathogenic mutation c.1718T>G (p.Val573Gly) in *DNMT1* gene that is associated to sensory predominant neuropathy, sensorineural hearing loss, cognitive decline, cerebellar ataxia, and REM sleep behavior disorder.

Funding

This work has not received any contribution, grant or scholarship.

Conflicts of interest

The authors have no conflicts of interest to declare.

Ethical disclosures

Protection of human and animal subjects. The authors declare that the procedures followed were

in accordance with the regulations of the relevant clinical research ethics committee and with those of the Code of Ethics of the World Medical Association (Declaration of Helsinki).

Confidentiality of data. The authors declare that they have followed the protocols of their work center on the publication of patient data.

Right to privacy and informed consent. The authors have obtained the written informed consent of the patients or subjects mentioned in the article. The corresponding author is in possession of this document.

References

1. Fox R, Ealing J, Murphy H, Gow DP, Gosal D. A novel DNMT1 mutation associated with early onset hereditary sensory and autonomic neuropathy, cataplexy, cerebellar atrophy, scleroderma, endocrinopathy, and common variable immune deficiency. *J Peripher Nerv Syst.* 2016;21:150–3.
2. Sun Z, Wu Y, Ordog T, Baheti S, Nie J, Duan X, et al. Aberrant signature methylome by DNMT1 hot spot mutation in hereditary sensory and autonomic neuropathy 1E. *Epigenetics.* 2014;9:1184–93.
3. Klein CJ, Botuyan MV, Wu Y, Ward CJ, Nicholson GA, Hammans S, et al. Mutations in DNMT1 cause hereditary sensory neuropathy with dementia and hearing loss. *Nat Genet.* 2011;43:595–600.
4. Winkelmann J, Lin L, Schormair B, Kornum BR, Faraco J, Plazzi G, et al. Mutations in DNMT1 cause autosomal dominant cerebellar ataxia, deafness and narcolepsy. *Hum Mol Genet.* 2012;21:2205–10.
5. Baets J, Duan X, Wu Y, Smith G, Seeley WW, Mademan I, et al. Defects of mutant DNMT1 are linked to a spectrum of neurological disorders. *Brain.* 2015;138:845–61.
6. Bi H, Hojo K, Watanabe M, Yee C, Maski K, Saba S, et al. Expanded genetic insight and clinical experience of DNMT1-complex disorder. *Neurol Genet.* 2020;12:6:e456.
7. Easwaran HP, Schermelleh L, Leonhardt H, Cardoso MC. Replication-independent chromatin loading of Dnmt1 during G2 and M phases. *EMBO Rep.* 2004;5:1181–6.
8. Coelho P, Santos MO. First Portuguese patient presenting with hereditary sensory and autonomic neuropathy Type 1E associated with a novel mutation in DNMT1 gene. *Neurol Sci.* 2020;41:1289–90.