

Cutaneous epithelioid angiosarcoma on the retro-auricular region

Angiossarcoma cutâneo epitelióide na região retro-auricular

Catarina Correia^{1,a,*}, Sónia Fernandes¹, Mariana Cravo², Luís Soares de Almeida¹, and Paulo Filipe¹

¹Dermatology Department, Hospital de Santa Maria, Centro Hospitalar Universitário Lisboa Norte (CHULN); ²Dermatology Department, Instituto Português de Oncologia de Lisboa. Lisbon, Portugal

^aORCID: 0000-0003-3055-1674

An 82-year-old man presented to the dermatology clinic with a 9-month history of an erythematous-violaceous infiltrated, poorly delimited lobulated plaque, with cystic areas and erosions, localized on the left retro-auricular region and extending to the occipital area (Fig. 1). There were no local symptoms or palpable cervical lymphadenopathy.

Skin biopsy and immunohistochemical staining revealed extensive infiltration of the dermis by a vascular tumor with vessels lined by atypical hyperchromatic epithelioid endothelial cells (Fig. 2), expressing CD31 and D2-40/podoplanin (Fig. 3), typical of cutaneous epithelioid angiosarcoma. A Computed tomography (CT) scan did not disclose metastases. The patient received 7 cycles of paclitaxel with no response. Therefore, he was treated with surgery and adjuvant radiotherapy. After 17 months of follow-up, there was local recurrence in the left pre-auricular region, and metastases in the cervical ganglion and left parotid were demonstrated by a positron emission tomography scan. Complete radical parathyroidectomy en bloc with the skin and the sternocleidomastoid muscle was performed. After 20 months of follow-up, pulmonary and hepatic metastases were seen on a CT scan and the patient died on the following month.

Discussion

Angiosarcoma is a very aggressive and rare malignant neoplasm that develops from vascular endothelial cells, mainly arising in superficial soft tissues and skin^{1,2}. Cutaneous angiosarcoma (CA) represents 1.6% of all cutaneous sarcomas, usually presenting on the neck or head of older individuals. In addition, it may occur in the presence of chronic lymphedema of the limbs (Stewart-Treves syndrome) or in areas previously submitted to radiotherapy²⁻⁵. The diagnosis of CA is often delayed because the initial clinical appearance is often subtle and non-specific. The clinical presentation of CA varies from multifocal indurated plaques and nodules to ill-defined bruise-like lesions²⁻⁴. Histopathologically, CA includes both poorly and well-differentiated tumors that can be confused with benign vascular neoplasms^{2,3}. Epithelioid angiosarcoma, a specific and rare variant of angiosarcoma, is defined by the preponderance of round or polygonal cells with ample eosinophilic cytoplasm and vesicular nuclei. The differential diagnosis includes melanoma, carcinoma, and lymphoma^{2,4}.

CA has a local recurrence rate of 63% and a 5-year survival rate of 10-35%. Furthermore, metastases develop in 36% of patients, with the lung, liver, and bones being the most common affected organs. Male gender,

Corresponding author:

*Catarina Correia

E-mail: catarinacorreia03@gmail.com

2797-5001 / © 2021 Portuguese Society of Dermatology and Venereology. Published by Permanyer. This is an open access article under the CC BY-NC-ND license (<http://creativecommons.org/licenses/by-nc-nd/4.0/>).

Received: 23-07-2021

Accepted: 29-09-2021

DOI: 10.24875/PJD.M22000016

Available online: 16-05-2022

Port J Dermatol and Venereol. 2022;80(1):77-78

www.portuguesejournalofdermatology.com

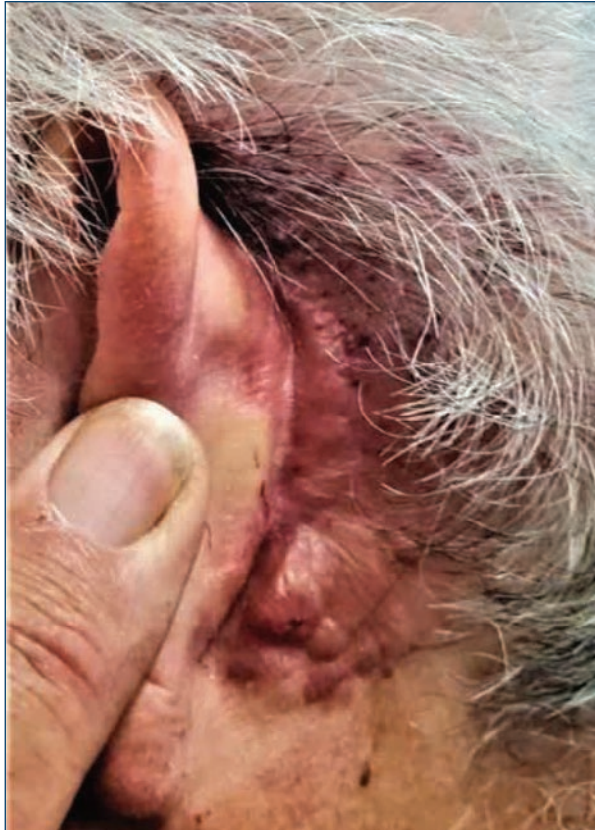

Figure 1. An erythematous-violaceous infiltrated, poorly delimited lobulated plaque, with cystic reas and erosions on the left retro-auricular region, extending to the occipital area.

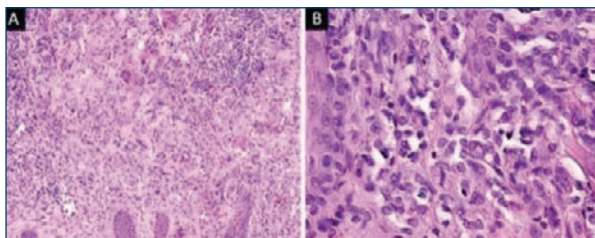


Figure 2. Histopathological features show extensive infiltration of the dermis by a vascular tumor with vessels lined by a combination of atypical hyperchromatic and epithelioid endothelial cells (A. H&E stain, $\times 100$; B. H&E stain, $\times 400$).

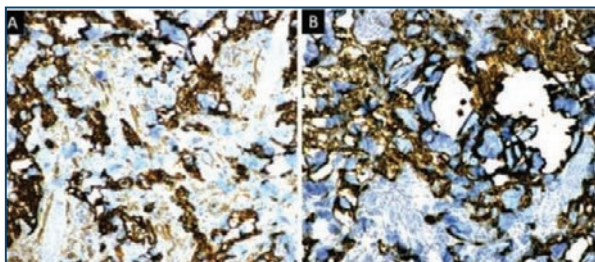


Figure 3. Immunohistochemical study ($\times 100$) showed that tumor cells were positive for **A:** CD31 and **B:** D2-40.

age over 50, history of smoking, cardiovascular disease, tumor size over 5 cm, scalp location, and presence of satellites at the time of diagnosis, are recognized as poor prognostic factors^{1,3,4}. Combining surgery and radiation is the recommended treatment of localized CA. Neoadjuvant chemotherapy may be considered in unresectable tumors. Metastatic angiosarcoma may show some response to a variety of therapies, such as anthracyclines and taxanes, targeted therapies such as tyrosine kinase inhibitors (pazopanib, sorafenib, axitinib, or regorafenib), vascular endothelial growth factor receptor inhibitors (bevacizumab or regorafenib), carotuximab (a monoclonal antibody to endoglin) and checkpoint inhibitors (pembrolizumab, durvalumab, and tremelimumab). However, most cases of metastatic angiosarcoma prove fatal¹⁻⁵. Therefore, early recognition and treatment of this aggressive malignancy are required for the best outcome³.

Funding

None.

Conflicts of interest

None.

Ethical disclosures

Protection of human and animal subjects. The authors declare that no experiments were performed on humans or animals for this investigation.

Confidentiality of data. The authors declare that they have followed the protocols of their work center on the publication of patient data and that all the patients included in the study have received sufficient information and have given their informed consent in writing to participate in that study.

Right to privacy and informed consent. The authors have obtained the informed consent of the patients and/or subjects mentioned in the article. The author for correspondence is in possession of this document.

References

1. Ishida Y, Otsuka A, Kabashima K. Cutaneous angiosarcoma: update on biology and latest treatment. *Curr Opin Oncol.* 2018;30:107–12.
2. Requena C, Alsina M, Morgado-Carrasco D, Cruz J, Sanmartín O, Serra-Guillén C, et al. Kaposi sarcoma and cutaneous angiosarcoma: guidelines for diagnosis and treatment. *Actas Dermosifiliogr.* 2018;109: 878–87.
3. Dossett LA, Harrington M, Cruse CW, Lavey RS, Cheong D, Forster MR, et al. Cutaneous angiosarcoma. *Curr Probl Cancer.* 2015;39:258–63.
4. Shustef E, Kazlouskaya V, Prieto VG, Ivan D, Aung PP. Cutaneous angiosarcoma: a current update. *J Clin Pathol.* 2017;70:917–25.
5. Florou V, Wilky BA. Current and future directions for angiosarcoma therapy. *Curr Treat Options Oncol.* 2018;19:14.