

Acral subungual lentiginous melanoma: The importance of early diagnosis and treatment

Melanoma lentiginoso subungueal acral: a importância do diagnóstico e tratamento precoces

Rodrigo César Davanço^{1,a*}, Rafael Amaro¹, Domingos Jordão Neto¹, Carolina Brandão Milanez¹, and Aline Sperandio Porto Rezende²

¹Department of Dermatology; ²Department of Histopathology, Heliópolis Hospital Complex, São Paulo, Brazil

^aORCID: 0000-0002-2254-8400

Abstract

Acral lentiginous melanoma is uncommon, representing about 4–6% of all melanomas that affect the Caucasian population, but it is the most frequent form of melanoma in Asian and African descendants, with a prevalence above 50%. Peak of incidence is around the sixth decade of life and affects both sexes equally. The etiology is uncertain, but it is suspected that local trauma and traumatic stress are part of the possible triggering factors. Onychomycosis, subungual hematoma, and striated melanonychia generated by a nevus in the nail matrix are part of the differential diagnosis.

We present the case of a young patient with melanonychia in the first right finger, with recent onset and progressive alteration, both in color and in the width of the melanonychia, whose histopathology confirmed the diagnosis of subungual melanoma *in situ*. A surgical approach with removal of the nail apparatus and conservation of the distal phalanx has been successful with no relapse after two years.

Keywords: Melanoma. MART-1 antigen. Nevi and melanoma.

Introdução

O melanoma lentiginoso acral é incomum, representando cerca de 4 a 6% de todos os melanomas que afetam a população caucasiana, porém é a forma mais frequente em descendentes de asiáticos e africanos, com prevalência acima de 50%. O pico de incidência é por volta da sexta década de vida e afeta ambos os sexos de forma igualitária. A etiologia é incerta, porém suspeita-se que o trauma local e o stress traumático fazem parte dos possíveis fatores desencadeantes. Onicomiose, hematoma subungueal e a melanoníquia estriada gerada por um nevo na matriz ungueal fazem parte do diagnóstico diferencial.

Apresentaremos o caso de uma paciente jovem com melanoníquia em primeiro quirodáctilo direito, de início recente e com alteração progressiva da lesão, tanto na coloração como na espessura das linhas. O estudo histopatológico confirmou o diagnóstico de melanoma subungueal *in situ*. A abordagem cirúrgica com remoção do aparato ungueal e conservação da falange distal mostrou-se eficaz e sem recidiva ao fim de 2 anos de seguimento clínico.

Palavras-chave: Melanoma. Antígeno MART-1. Nevos e melanoma.

Corresponding author:

*R.C. Davanço

E-mail: rodrigodavanco@gmail.com

2797-5001 / © 2022 Portuguese Society of Dermatology and Venereology. Published by Permanyer. This is an open access article under the CC BY-NC-ND license (<http://creativecommons.org/licenses/by-nc-nd/4.0/>).

Received: 05-12-2021

Accepted: 20-03-2022

DOI: 10.24875/PJD.M22000018

Available online: 02-08-2022

Port J Dermatol and Venereol. 2022;80(2):151-154

www.portuguesejournalofdermatology.com

Case report

A 37-year-old, female patient, phototype IV, working as a dressmaker, reported a pigmented linear lesion on the first right finger for five months, that progressively suffered a color change and increase in diameter. She reported no local trauma, other associated symptoms, or family history of melanoma.

Dermatological examination showed an irregular, longitudinal brownish linear nail pigmentation, with a greater diameter near the proximal nail fold. On dermoscopy, the lesion had an irregular black to dark brown background, with breakage of parallelism, a positive Hutchinson's micro sign and an enlarged base with distal narrowing (Fig. 1). Absence of palpable lymph nodes on physical examination. We opted for an excisional biopsy of the nail matrix, with 3 mm margins. The anatomopathological report was compatible with *in situ* acral lentiginous melanoma and immunohistochemistry showed positive staining for Melan A and Ki67 (90%). Collagen IV expression was intact in the basement membranes (Figs. 2–5). The patient was referred to the oncology clinic, where the nail apparatus was removed surgically while preserving the distal phalanx (Fig. 6). The patient remains under clinical follow-up with dermatology and oncology every six months and is free of lesions for two years.

Discussion

Acral lentiginous melanoma (ALM), the most common clinical presentation of melanoma in African and Asian descent^{1,3}, is a rare subtype in Caucasians with data in the literature ranging from 2 to 6%. ALM has an equal incidence in men and women and predominates in individuals between 50 and 70 years of age^{3,6,7}. Any histological subtype of melanoma that occurs on the palms, soles, subungual or dorsum of hands and feet is considered acral melanoma^{3,8}. The etiology is uncertain, but several factors such as trauma, chronic inflammation, and mechanical stress have been proposed^{3-5,8}. As it is a pathology with few symptoms in the initial stages, added to the fact that it affects more advanced age groups and the inherent limitation for self-examination in acral regions, it is often detected in more advanced stages³. Clinically, there may be a pigmented longitudinal band (melanonychia), brownish to blackish, asymmetrical, with an irregular edge, and there may be dissemination of pigmentation to the proximal nail fold, giving rise to the Hutchinson sign, as in the present case. In more advanced stages, nail dystrophy, complete destruction of the nail plate and ulcerations may

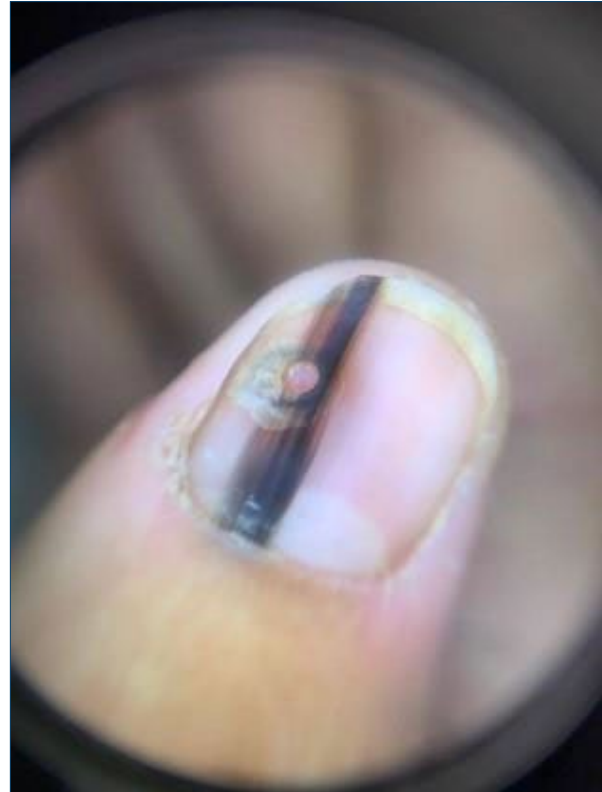

Figure 1. On dermoscopy: blackish-brown longitudinal lines, which are irregular both in color and thickness.

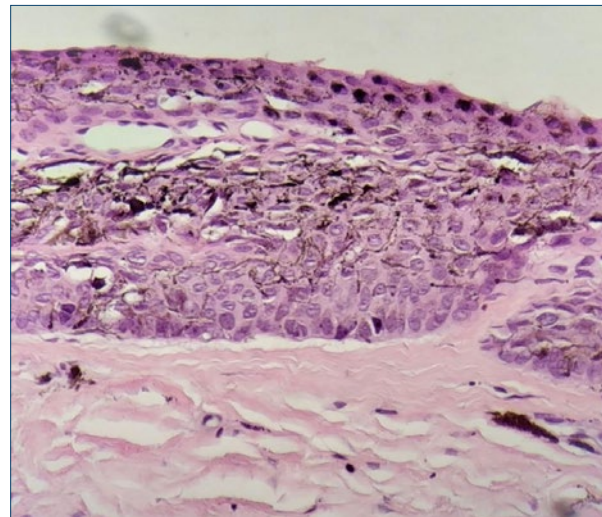


Figure 2. Proliferation of atypical intraepithelial melanocytes with abundant melanin (H&E 400X).

be present^{1,6,7}. Genetic alterations may be involved in melanoma, with the mutation in the receptor tyrosine kinase (KIT) being the most frequent in ALM (15–40%), whereas in other melanoma subtypes (superficial spreading melanoma and nodular melanoma) mutations occur more commonly in NRAS (17%), BRAF (50%) or PTEN⁹.

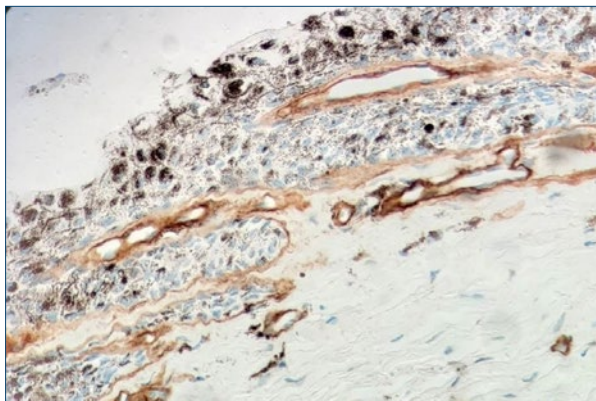


Figure 3. Immunohistochemistry with Collagen IV staining shows an intact basement membrane demarking neoplastic cells (400X).

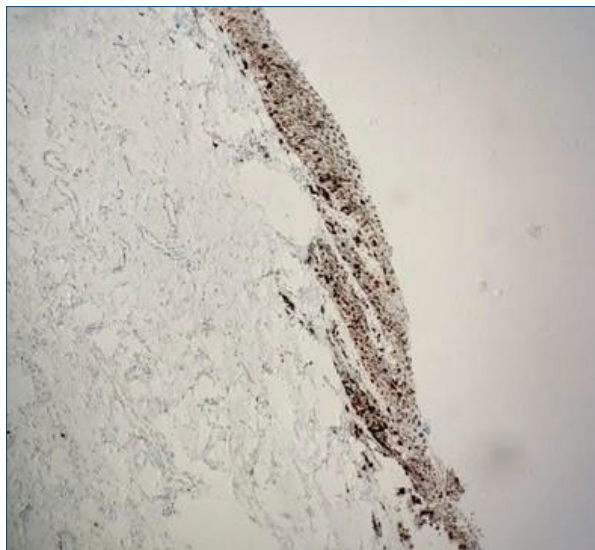

Figure 6. Final result 6 months after removal of the nail apparatus with preservation of the distal phalanx.

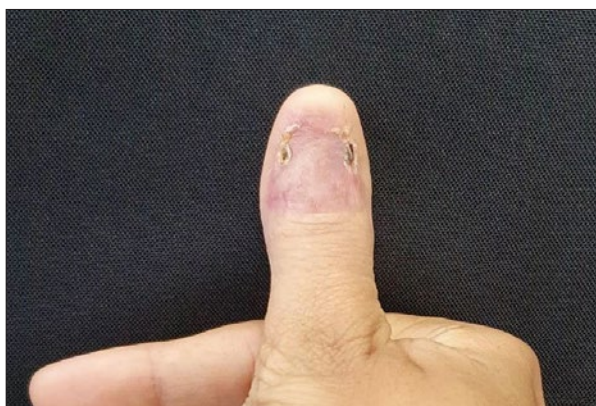


Figure 4. Immunohistochemistry staining with MELAN-A showing atypical melanocytes scattered in epidermis (400X).

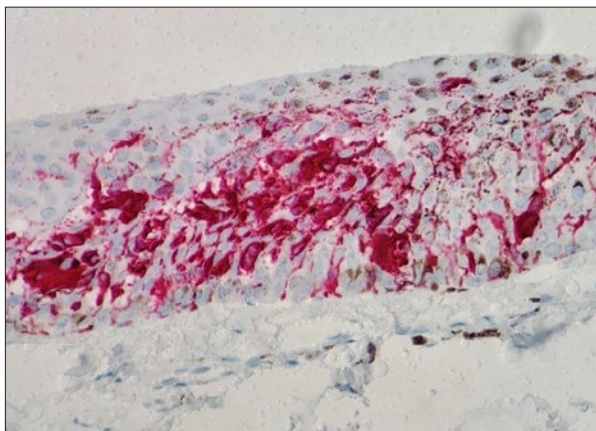


Figure 5. Immunohistochemistry staining with Ki-67 with positivity in 90% of neoplastic epidermal cells in epidermis (40X).

Other benign conditions can produce a sign similar to Hutchinson's (pseudo-Hutchinson) such as Addison's disease, HIV infection, Bowen's disease, racial pigmentation (phototypes V and VI), and malnutrition, among others. Whereas the most common form of longitudinal melanonychia in adults is melanocytic activation, in children benign melanocytic nevus is the more frequent^{7,8}.

Dermoscopy is an additional tool that can help distinguish between benign and malignant pigmentary lesions^{1,7}. Suspicious lesions may present irregular longitudinal lines, with a diameter greater than 3 mm, abrupt interruption of parallelism in some areas, brown or black color and ill-defined borders.

Biopsy is indicated in suspicious lesions, namely those appearing after puberty, especially from the fourth to the sixth decade of life, any acquired lesion in patients with a personal history of melanoma and lesions with rapid and progressive growth^{6,9}. Lesions smaller than 3 mm in diameter can be biopsied using 2 biopsy punches, one of 6 mm with removal of the pigmented nail plate and the other of 3–4 mm performed on the nail matrix. However, in lesions with a diameter between 3–6 mm and with pigment in the nail matrix, a transverse biopsy in the matrix is indicated, and removal in blocks with a "U" flap may be necessary if there is pigment in the proximal nail matrix⁹.

Histologically, confluent dendritic or epithelioid melanocytes can be identified, alone or in nests, at the dermoepidermal junction. Pagetoid migration may occur

and dermal invasion takes the form of atypical epithelioid cords or nests³. Immunohistochemistry staining with markers such as MART-1, Melan-A, S-100, HMB45, and NKI/C3 complements the diagnosis, and a positive MART-1 or HMB45 and S100 protein with negative cyto-keratin confirms the diagnosis of melanoma⁷.

Due to the proximity of the nail matrix to the underlying bone, wide excision with amputation of the phalanx is considered the first-line therapy in cases of melanoma of the nail unit, but additional therapies may be necessary depending on the extent of the lesion^{1,6}. In *in situ* lesions, currently, more conservative surgeries are indicated, such as amputation of the distal phalanx, thus preserving the proximal phalanx^{1,3,7}. In these lesions or others that are minimally invasive, some authors suggest wide local excision with removal of the nail plate, bed, and matrix, thus avoiding limb amputation^{6,8-10}. In cases of locally advanced disease, the level of amputation of the phalanx will depend on the thickness and depth of the lesion⁹, while in metastatic disease the therapeutic options are chemotherapy, radiotherapy, targeted molecular therapy, and immunotherapy. Nevertheless, most agents used in targeted therapy are indicated for melanomas with mutations in BRAF, NRAS, and PTEN, whereas in the acral lentiginous subtype, the main mutation is in KIT, leaving few therapeutic options such as imatinib and sunitinib, both with variable clinical response^{1,3,7}.

As ALM is an infrequent subtype and with a worse prognosis when compared to other subtypes, early diagnosis and an adequate therapeutic approach are essential for a better evolution of the condition, with greater chances of cure.

Funding

None.

Conflicts of interest

None.

Ethical disclosures

Protection of people and animals. The authors declare that for this research no experiments on human beings and/or animals were performed.

Confidentiality of data. The authors declare that they have followed the protocols of their work centre about the publication of patient data.

Right to privacy and written consent. The authors declare that no patient data appear in this article.

References

1. Nakamura Y, Fujisawa Y. Diagnosis and management of acral lentiginous melanoma. *Curr Treat Options Oncol*. 2018 Jun 27;19(8):42. doi: 10.1007/s11864-018-0560-y. PMID: 29951919.
2. Lino-Silva LS, Zepeda-Najar C, Salcedo-Hernández RA, Martínez-Said H. Acral lentiginous melanoma: survival analysis of 715 cases. *J Cutan Med Surg*. 2019 Jan/Feb;23(1):38–43. doi: 10.1177/1203475418800943. Epub 2018 Sep 15. PMID: 30221995.
3. Goydos JS, Shoen SL. Acral lentiginous melanoma. *Cancer Treat Res*. 2016;167:321–9. doi: 10.1007/978-3-319-22539-5_14. PMID: 26601870.
4. Darmawan CC, Jo G, Montenegro SE, Kwak Y, Cheol L, Cho KH, *et al*. Early detection of acral melanoma: a review of clinical, dermoscopic, histopathologic, and molecular characteristics. *J Am Acad Dermatol*. 2019 Sep;81(3):805–12. doi: 10.1016/j.jaad.2019.01.081. Epub 2019 Feb 5. PMID: 30731177.
5. Cust AE. Prognostic features for acral lentiginous melanoma. *Br J Dermatol*. 2018 Feb;178(2):311–2. doi: 10.1111/bjd.16163. PMID: 29441559.
6. Duarte AF, Correia O, Barros AM, Azevedo R, Haneke E. Nail matrix melanoma in situ: conservative surgical management. *Dermatology*. 2010;220(2):173–5. doi: 10.1159/000266038. Epub 2009 Dec 11. PMID: 20016126.
7. Littleton TW, Murray PM, Baratz ME. Subungual Melanoma. *Orthop Clin North Am*. 2019 Jul;50(3):357–66. doi: 10.1016/j.ocl.2019.03.003. PMID: 31084838.
8. Ruffolo AM, Sampath AJ, Kozlow JH, Neumeister MW. Melanoma of the hands and feet (with reconstruction). *Clin Plast Surg*. 2021 Oct;48(4):687–98. doi: 10.1016/j.cps.2021.05.009. Epub 2021 Jun 27. PMID: 34503729.
9. Braun RP, Baran R, Le Gal FA, Dalle S, Ronger S, Pandolfi R, *et al*. Diagnosis and management of nail pigmentations. *J Am Acad Dermatol*. 2007 May;56(5):835–47. doi: 10.1016/j.jaad.2006.12.021. Epub 2007 Feb 22. PMID: 17320240.
10. Lieberherr S, Cazzaniga S, Haneke E, Hunger RE, Seyed Jafari SM. Melanoma of the nail apparatus: a systematic review and meta-analysis of current challenges and prognosis. *J Eur Acad Dermatol Venereol*. 2020 May;34(5):967–76. doi: 10.1111/jdv.16121. Epub 2020 Jan 6. PMID: 31788861.