

# Pediatric ashy dermatosis: what to expect?

## *Dermatose cinzenta pediátrica: o que esperar?*

Tiago Fernandes Gomes<sup>1,a</sup>, Katarina Kieselová<sup>1,b</sup>, Fernanda Cunha<sup>2,c</sup>, Cristina Amado<sup>2,d</sup>, and Felicidade Santiago<sup>1,e</sup>

<sup>1</sup>Dermatology Department; <sup>2</sup>Pathology Department, Centro Hospitalar de Leiria, Portugal  
ORCID: <sup>a</sup>0000-0003-2469-4871; <sup>b</sup>0000-0002-0064-7571; <sup>c</sup>0000-0002-6847-673X; <sup>d</sup>0000-0003-2215-6770; <sup>e</sup>0000-0003-2402-4229

### Abstract

Ashy dermatosis is a pigmentation dermatosis that belongs to the group of acquired macular hyperpigmentation disorders of uncertain etiology. Although the adulthood forms usually occur in higher Fitzpatrick skin types, pediatric cases are more common in lower phototypes. The authors report two cases of pre-pubertal ashy dermatosis and perform a brief review of literature to highlight the differences in epidemiology and course of the disease in children and adults.

**Keywords:** Ashy dermatosis. Erythema dyschromicum perstans. Pigmentation. Dermis.

### Resumo

A dermatose cinzenta é uma doença da pigmentação que pertence ao grupo dos distúrbios de hiperpigmentação macular adquirida de etiologia incerta. Embora as formas do adulto ocorram habitualmente em fotótipos cutâneos de Fitzpatrick elevados, os casos pediátricos são mais comuns em fotótipos baixos. Os autores reportam dois casos de dermatose cinzenta em idade pediátrica e descrevem uma breve revisão da literatura para salientar as diferenças de epidemiologia e de curso da doença em crianças e adultos.

**Palavras-chave:** Dermatose cinzenta. Eritema discrómico perstans. Pigmentação. Derme.

### Introduction

Ashy dermatosis (AD) is a pigmentation dermatosis that belongs to the group of acquired macular hyperpigmentation disorders of uncertain etiology. It presents with blue-gray macules, symmetrically located on the trunk, neck and upper extremities<sup>1</sup>. Although the adulthood form is more common in higher Fitzpatrick skin types, pediatric cases are more common in

Caucasian individuals with lower phototypes<sup>1</sup>. The authors report two cases of AD in pre-pubertal age and highlight the differences in epidemiology and course of the AD in children in comparison with adults.

### Case report 1

An 11-year-old boy, Fitzpatrick skin type III, presented with multiple blue to gray oval macules and patches

#### Corresponding author:

\*Tiago Fernandes Gomes  
E-mail: tiagofgomesd@gmail.com

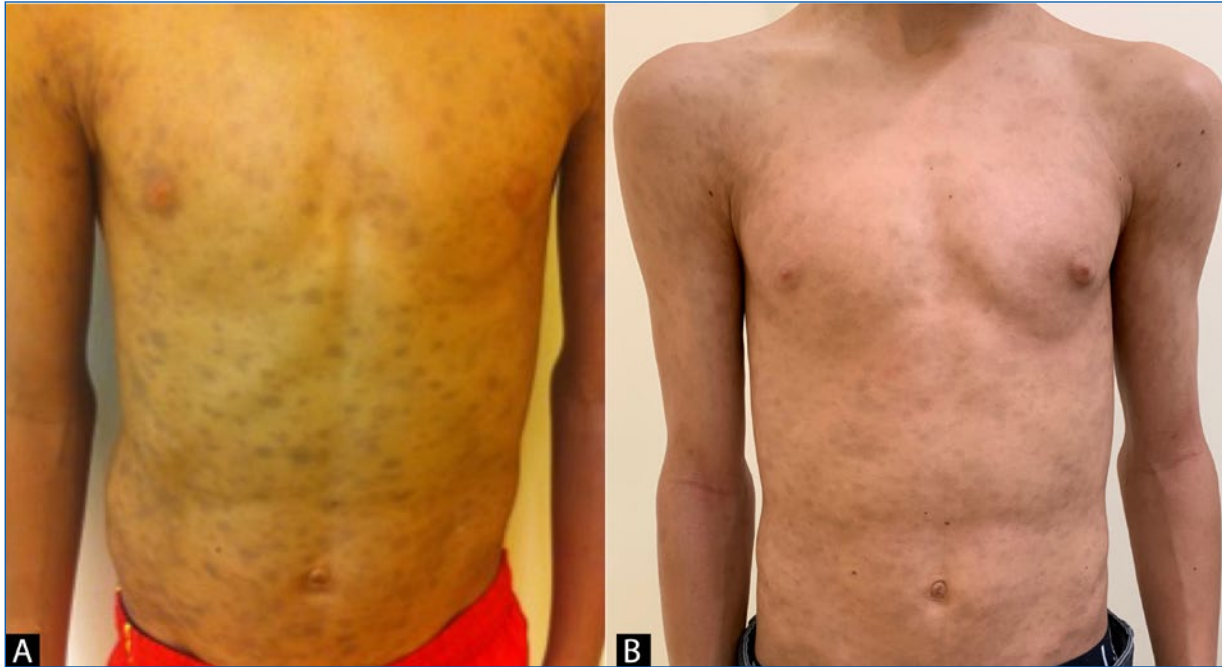Received: 01-02-2022

Accepted: 01-06-2022  
DOI: 10.24875/PJDV.M22000033

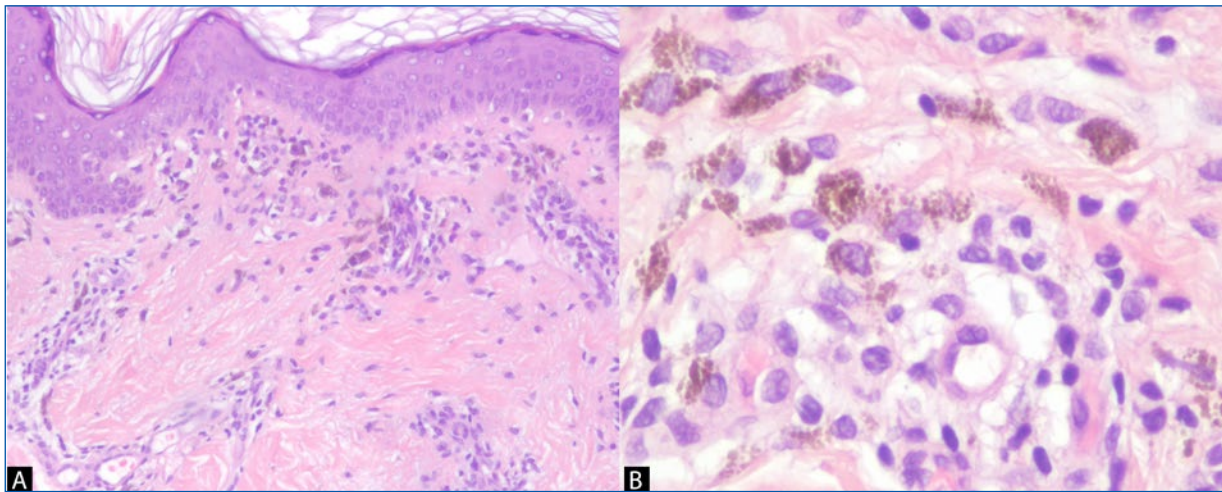
Available online: 24-10-2022

Port J Dermatol and Venereol. 2022;80(3):217-221  
[www.portuguesejournalofdermatology.com](http://www.portuguesejournalofdermatology.com)

2797-5001 / © 2022 Portuguese Society of Dermatology and Venereology. Published by Permanyer. This is an open access article under the CC BY-NC-ND license (<http://creativecommons.org/licenses/by-nc-nd/4.0/>).



**Figure 1.** **A:** patient 1 at the first visit. **B:** patient 3 years of follow-up.

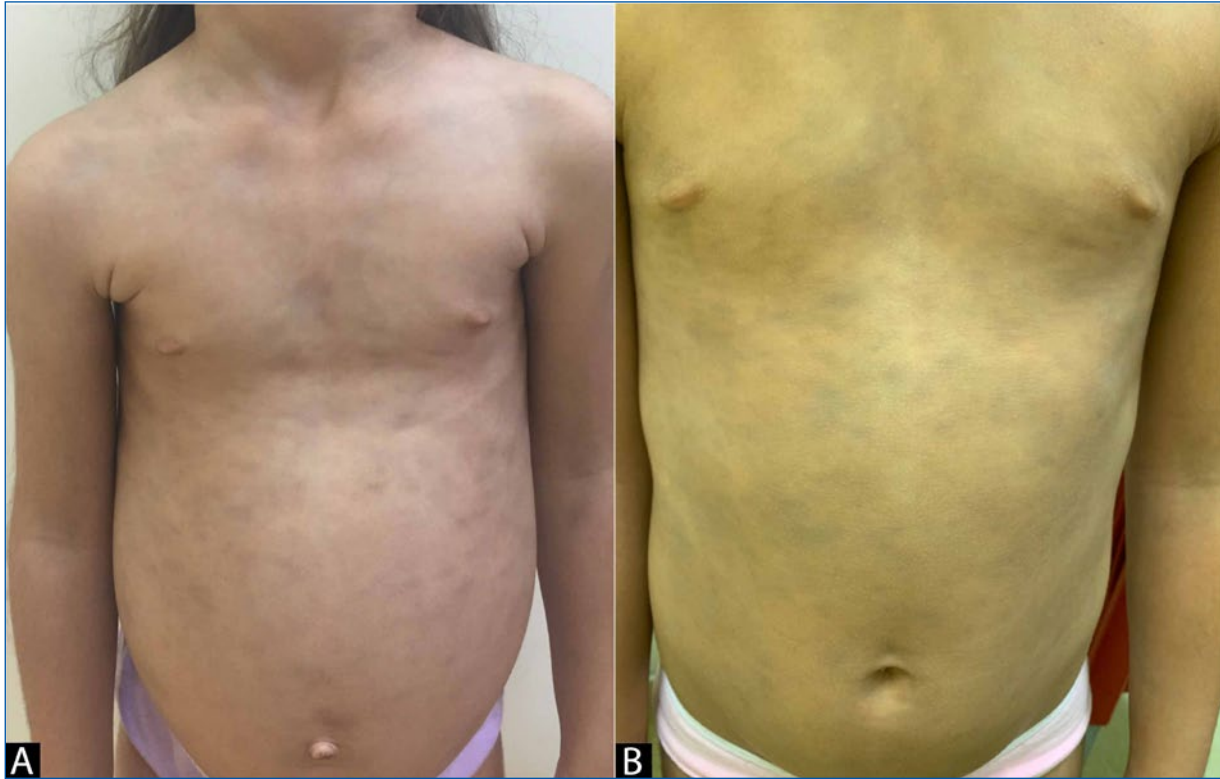


**Figure 2.** Histopathology of patient 1 with focal vacuolar changes in basal stratum of epidermis, mild inflammatory perivascular infiltrate, dehiscent pigment with interstitial and perivascular melanophages (**A:** H&E, x100; **B:** H&E, x400).

between 5 and 15 mm, on his trunk, neck and proximal thighs (Fig. 1A). No erythematous border of the lesions was observed. The lesions had appeared suddenly one month before the dermatological observation and were asymptomatic. He was otherwise healthy and there was no previous intake of medication. His twin brother had no similar lesions. He was sent to the Dermatology Department with a diagnosis of multiple ecchymoses. His complete blood count and coagulation times were within the normal range. There was no history of

trauma. A skin biopsy was performed and histopathology revealed focal vacuolar changes in basal stratum of the epidermis, a mild inflammatory perivascular infiltrate and dehiscent pigment with interstitial and perivascular melanophages (Fig. 2).

A diagnosis of AD was made. The boy started treatment with a mometasone furoate 0.1% cream for 4 weeks, with no improvement of the dermatosis. At 3 years' follow-up, lesions remain unchanged (Fig. 1B).



**Figure 3.** **A:** patient 1 at the first visit. **B:** patient 2 years of follow-up.

## Case report 2

A 5-year-old girl, Fitzpatrick skin type II, presented with 5-20 mm, grayish oval macules on her trunk (Fig. 3A) with no erythematous rim. The lesions had a gradual onset for 2 months. At the same time, the girl developed abdominal pain with diarrhea which led to the diagnosis of celiac disease. A biopsy of a cutaneous lesion revealed abundant perivascular macrophages with intracytoplasmic brownish pigment and no epidermal changes (Fig. 4).

With a diagnosis of AD and celiac disease, the child started a gluten free diet with improvement of the gastrointestinal symptoms but no improvement of cutaneous lesions. No topical or systemic treatment was attempted. At 2 years' follow-up, she maintains the same lesions (Fig. 3B).

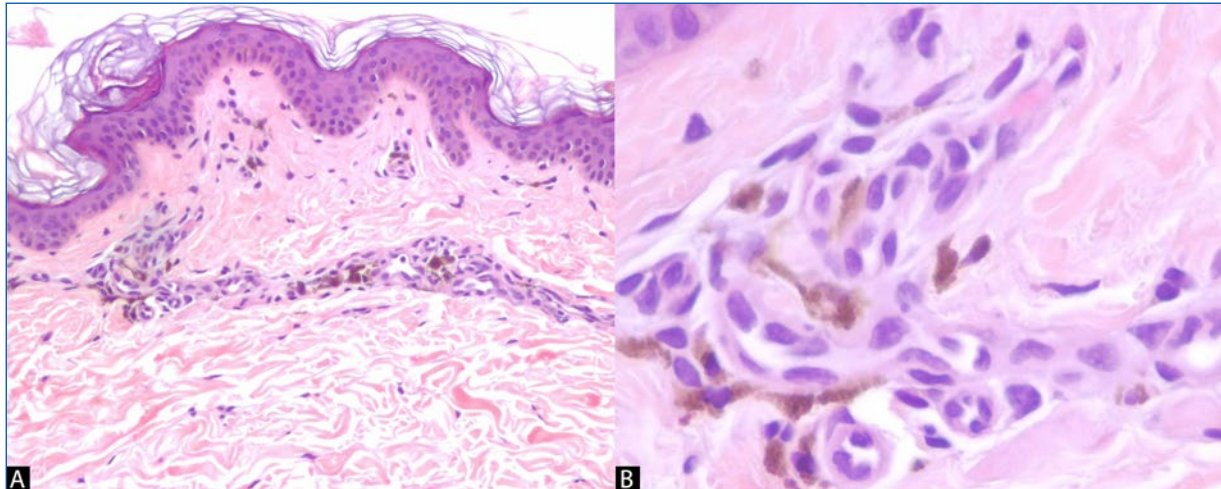
## Discussion

Ashy Dermatitis (AD) was first described in individuals from El Salvador in 1957<sup>2</sup>. AD patients experience an onset of bluish or grayish macules, sometimes with

an erythematous and elevated rim which eventually disappears within several months. Trunk, neck and upper limbs are the most commonly involved areas followed by face and lower limbs<sup>1,3</sup>. Palms and soles are usually unaffected<sup>4,5</sup>. Although it usually spares the mucous membranes, lesions on the oral cavity have been reported<sup>6</sup>. In most cases this is an asymptomatic condition but some patients may refer mild pruritus<sup>4</sup>.

Many authors consider AD and erythema dyschromicum perstans (EDP) as the same disorder. However, a consensus published by a group of pigmentary disorders experts consider these as two separate entities, with the major difference between them being the presence of an erythematous border in the early active phase of EDP<sup>2</sup>. If there is no history or active presence of the erythematous border, it should be considered as AD<sup>1,2</sup>. Chang et al. reported that only 17.6% of 68 Korean patients with AD/EDP presented with the erythematous raised border<sup>3</sup>.

There are some interesting differences between childhood and adulthood cases. While most adult patients are Hispanic with higher phototypes, children affected are usually Caucasian and have lower phototypes<sup>4,7</sup>. Another difference is the spontaneous improvement or resolution in 50-69% of pre-pubertal patients,



**Figure 4:** Histopathology of patient 2 with abundant perivascular macrophages with intracytoplasmic brownish pigment (**A:** H&E, x100; **B:** H&E, x400).

which contrasts with the persistent course in adults<sup>2,7</sup>. However, the evidence regarding pediatric patients is still limited, as few reports have addressed this dermatosis in children<sup>4,7</sup>.

Although there were some reports of AD following drugs and infections, the etiology mostly remains unknown<sup>2,3,7,8</sup>. In our patients, no clear trigger was identified except for the almost simultaneous onset of celiac disease on the second patient. However, we could not make a clear relation between these two entities as the gluten-free diet improved celiac disease manifestations but did not affect AD. A genetic contribution has also been proposed to contribute to the development of the AD<sup>2</sup>. However this could not be supported by our cases, since the first patient had a twin brother without lesions.

Primary histopathologic findings include pigment incontinence and melanophages in the dermis, along with mild to moderate superficial perivascular lymphocytic infiltration. Usually there is basal vacuolar degeneration and a focal or lichenoid pattern with colloid bodies along the dermoepidermal junction<sup>1,4</sup>.

Basal vacuolar degeneration and edematous papillary dermis with lymphocytic infiltrate indicate active lesions, whereas inactive lesions show melanophages and pigment incontinence in the dermis, with no inflammation<sup>3</sup>. This is in accordance with both our cases. In case 1, which presented to our department few weeks after the onset of the dermatosis, we found vacuolar alterations in the basal layer, with a mononuclear infiltrate, suggesting an active phase. In case 2, we did not find these aspects typical of the active phase, which is compatible with the longer

duration of the dermatosis of the child before presenting to our consultation. However, the lack of the lichenoid aspects in case 2 makes it difficult to assume a definitive diagnosis of AD over idiopathic eruptive macular pigmentation (IEMP).

Other conditions may mimic AD/EDP, such as lichen planus pigmentosus (LPP) and IEMP.

Lichen planus pigmentosus (LPP) most frequently affects sun-exposed areas, such as the face and neck, but can also affect flexural folds and rarely the oral mucosa<sup>1,9</sup>. While AD typically has a stable course, LPP is more likely to have a wax and waning history<sup>9</sup>. Histopathology alone cannot differentiate between AD/EDP and LPP<sup>10</sup>. Dermoscopy has been described as a useful tool when in doubt with LPP. In AD, dermoscopy shows gray-bluish small dots over a bluish background, whereas in LPP dots are brownish and larger than AD dots, and occur over a brownish background<sup>11</sup>.

Idiopathic eruptive macular pigmentation (IEMP) is an eruption of asymptomatic brownish macules, affecting the trunk, neck and proximal extremities, with no previous inflammatory lesions or drug exposure<sup>1</sup>. Lesions are typically smaller than the ones observed in AD<sup>2</sup>. IEMP affects both dark and light phototypes<sup>1</sup>. There is usually a hyperpigmentation of the basal layer of epidermis and prominent dermal melanophages, with no basal layer damage or lichenoid inflammatory infiltrate<sup>2,10</sup>. Lesions resolve without treatment in several months to years<sup>1</sup>.

There is no uniformly effective therapy for AD/EDP<sup>2</sup>, and most evidence regarding treatment results from case reports in adults. Although topical steroids are the most commonly used agents<sup>3,5</sup>, other options such as

topical hydroquinone<sup>3,9</sup>, topical calcineurin inhibitors<sup>5,12</sup> and topical tretinoin<sup>3,9</sup> have been described with variable outcomes. Numata et al. reported the disappearance of the erythematous halo of the EDP lesions in an adult after the use of a topical steroid, but pigmented macules and patches persisted<sup>13</sup>. Multiple systemic drugs have been tried in the treatment of AD/EDP in adults, such as isotretinoin<sup>14,15</sup>, minocycline<sup>3</sup>, clofazimine<sup>16</sup>, dapsone<sup>5,17</sup>, and oral steroids<sup>9,15</sup>. There is also a report of resolution of AD after the administration of pembrolizumab in a 62-year-old patient with squamous cell carcinoma of the lung<sup>18</sup>. Phototherapy with narrow band UVB has been successful in the treatment of a 17-year-old male<sup>19</sup>.

In both cases reported in this article, no systemic treatment was attempted due to the benign course of the disease and lack of and lack of an effective and safe medication available. Spontaneous improvement or resolution of the lesions is seen in the majority of pre-pubertal children<sup>2,4</sup>. In a cohort of patients observed between 3 and 76 years, complete clearing was reported in 2%, improvement in 43.1%, worsening in 5.9%, and 49.0% showed no significant change<sup>3</sup>. Silverberg et al. reported complete clearance of AD in 5 of 8 pre-pubertal patients, with an average clearance time of 2.5 years and the longest duration of 5 years. The remaining three patients missed the follow-up<sup>7</sup>.

## Conclusion

AD is a benign condition observed more common in Hispanic adult patients. However, considering the pre-pubertal age, it is more frequently observed in Caucasian children. Its insidious and persistent course may alarm the child's caregivers. Therefore, it is important to explain them that although no efficient and safe therapy exists, most children will progress towards a spontaneous improvement or resolution.

## Presentations

Part of the current work has been presented at the Spring Meeting of the Portuguese Society of Dermatology and Venereology, in May 25, 2019, Curia, Portugal.

## Ethical disclosures

**Protection of human and animal subjects.** The authors declare that the procedures followed were in accordance with the regulations of the relevant clinical research ethics committee and with those of the Code

of Ethics of the World Medical Association (Declaration of Helsinki).

**Confidentiality of data.** The authors declare that they have followed the protocols of their work center on the publication of patient data.

**Right to privacy and informed consent.** The authors have obtained the written informed consent of the patients or subjects mentioned in the article. The corresponding author is in possession of this document.

## References

1. Udompanich S, Vachiramon V. Acquired macular pigmentation of unknown etiology. *J Clin Aesthet Dermatol.* 2019;12:38–46.
2. Kumarasinghe SPW, Pandya A, Chandran V, et al. A global consensus statement on ashy dermatosis, erythema dyschromicum perstans, lichen planus pigmentosus, idiopathic eruptive macular pigmentation, and Riehl's melanosis. *Int J Dermatol.* 2019;58:263–72. doi:10.1111/ijd.14189
3. Chang SE, Kim HW, Shin JM, et al. Clinical and histological aspect of erythema dyschromicum perstans in Korea: a review of 68 cases. *J Dermatol.* 2015;42:1053–7. doi:10.1111/1346-8138.13002
4. Torreló A, Zaballos P, Colmenero I, Mediero IG, de Prada I, Zambrano A. Erythema dyschromicum perstans in children: a report of 14 cases. *J Eur Acad Dermatol Venereol.* 2005;19:422–6. doi:10.1111/j.1468-3083.2005.01203.x
5. Antonov NK, Braverman I, Subtil A, Halasz CL. Erythema dyschromicum perstans showing resolution in an adult. *JAAD Case Rep.* 2015;1:185–7. doi:10.1016/j.jdc.2015.04.011
6. Rato M, Monteiro AF, Aranha J, Tavares E. Ashy dermatosis with involvement of mucous membranes. *An Bras Dermatol.* 2017;92:17–20. doi:10.1590/abd1806-4841.20176133
7. Silverberg NB, Herz J, Wagner A, Paller AS. Erythema dyschromicum perstans in prepubertal children. *Pediatr Dermatol.* 2003;20:398–403. doi:10.1046/j.1525-1470.2003.20505.x
8. de Melo CRF, de Sá MC, Carvalho S. Erythema dyschromicum perstans in a child following an enteroviral meningitis. *An Bras Dermatol.* 2017;92:137–8. doi:10.1590/abd1806-4841.201745144
9. Cheng HM, Chuah SY, Gan EY, Jhingan A, Thng STG. A retrospective clinico-pathological study comparing lichen planus pigmentosus with ashy dermatosis. *Australas J Dermatol.* 2018;59:322–7. doi:10.1111/ajd.12813
10. Chandran V, Kumarasinghe SP. Macular pigmentation of uncertain aetiology revisited: two case reports and a proposed algorithm for clinical classification. *Australas J Dermatol.* 2017;58:45–9. doi:10.1111/ajd.12428
11. Errichetti E, Angione V, Stinco G. Dermoscopy in assisting the recognition of ashy dermatosis. *JAAD Case Rep.* 2017;3:482–4. doi:10.1016/j.jdc.2017.06.022
12. Ercan N. Erythema dyschromicum perstans in an infant with positive Darier sign: a case report successfully treated with tacrolimus. *Dermatol Ther.* 2020;33:e14175. doi:10.1111/dth.14175
13. Numata T, Harada K, Tsuboi R, Mitsuhashi Y. Erythema dyschromicum perstans: identical to ashy dermatosis or not. *Case Rep Dermatol.* 2015;7:146–50. doi:10.1159/000437414
14. Wang F, Zhao Y-K, Wang Z, Liu J-H, Luo D-Q. Erythema dyschromicum perstans response to isotretinoin. *JAMA Dermatol.* 2016;152:841–2. doi:10.1001/jamadermatol.2015.6185
15. Diaz A, Gillihan R, Motaparthy K, Rees A. Combination therapy with prednisone and isotretinoin in early erythema dyschromicum perstans: a retrospective series. *JAAD Case Rep.* 2020;6:207–13. doi:10.1016/j.jdc.2019.12.015
16. Pinto-Almeida T, Caetano M, Alves R, Selores M. Ashy dermatosis - tratamento com clofazimina. *J Port Soc Dermatology Venereol.* 2013;70:365. doi:10.29021/spdv.70.3.15
17. Bahadir S, Cobanoglu U, Cimsit G, Yayli S, Alpay K. Erythema dyschromicum perstans: response to dapsone therapy. *Int J Dermatol.* 2004;43:220–2. doi:10.1111/j.1365-4632.2004.01984.x
18. Takeda K, Fujimura T, Tsuchiyama K, Lyu C, Aiba S. Pembrolizumab resolves adult ashy dermatosis developing in patients with squamous cell carcinoma of the lung. *J Dermatol.* 2019;46:271–3. doi:10.1111/1346-8138.14775
19. Leung N, Oliveira M, Selim MA, McKinley-Grant L, Lesesky E. Erythema dyschromicum perstans: a case report and systematic review of histologic presentation and treatment. *Int J Women's Dermatol.* 2018;4:216–2. doi:10.1016/j.jwd.2018.08.003