

Nevus or melanoma in a tattoo: a diagnostic pitfall

Nevo ou melanoma sobre tatuagem: dificuldades diagnósticas

Stephan Große-Büning^{1,2}, Florian Butsch², Marie Leger³, and Stephan Grabbe²

¹Medicorium, Oberursel, Germany; ²Department of Dermatology, University Medical Center, Mainz, Germany; ³Skin Cancer and Dermatology Institute, Nevada, USA

Abstract

The authors describe a 61-year-old male patient with two previous melanoma who developed a pigmented lesion on a tattoo that was difficult to diagnose on dermoscopy but histopathology revealed the third melanoma with 0.3 mm thickness. The authors call the attention to increasing incidence of melanoma in the German population in parallel with the increase in tattooing, which may delay the diagnosis of melanoma in tattooed skin. Therefore, they recommend performing early biopsies in pigmented lesions in tattoos, especially before laser treatment of tattoos.

Keywords: Melanoma. Melanocytic nevi. Tattoo.

Resumo

Os autores descrevem um doente do sexo masculino com 2 melanomas anteriores com lesão pigmentada sobre tatuagem, cujo diagnóstico dermatoscópico não foi claro, mas cuja histopatologia confirmou tratar-se de melanoma com uma espessura de 0.3 mm. Os autores chamam a atenção para o crescimento tanto da incidência do melanoma como do número de indivíduos com tatuagens, o que poder atrasar o diagnóstico de melanomas que ocorram na pele tatuada. Recomendam assim a realização de biópsias precoces em lesões pigmentadas sobre tatuagens, especialmente antes do seu tratamento com Laser.

Palavras-chave: Melanoma. Nevo melanocítico. Tatuagem.

Case report

A 61-year-old man skin type II presented to our outpatient clinic with a suspicious lesion within a tattoo on his right upper arm for an unknown period of time. On examination, he had a soft, sharply demarcated bluish papule measuring 7 mm with a smooth surface. The papule could be pressed into the level of the skin. Incident light microscopy revealed blue lacunae outside the tattoo and

blackish structureless portions in the area of the overlying tattoo (Fig. 1, black arrow). In addition, distal to the lesion described above, he had a symmetrical, irregularly pigmented, and approximately 5 mm in diameter brown macule. Incident light microscopy revealed an irregular internal structure consisting of reticular lines and clods with questionable heterochromia. The assessability to this lesion was considerably limited by the tattooing (Fig. 1, red arrow).

Corresponding author:

*Stephan Große-Büning

E-mail: grosse-buening@medicorium.de

2797-5001 / © 2022 Portuguese Society of Dermatology and Venereology. Published by Permanyer. This is an open access article under the CC BY-NC-ND license (<http://creativecommons.org/licenses/by-nc-nd/4.0/>).

Received: 01-05-2022

Accepted: 01-08-2022

DOI: 10.24875/PJDV.M22000036

Available online: 24-10-2022

Port J Dermatol and Venereol. 2022;80(3):231-234

www.portuguesejournalofdermatology.com

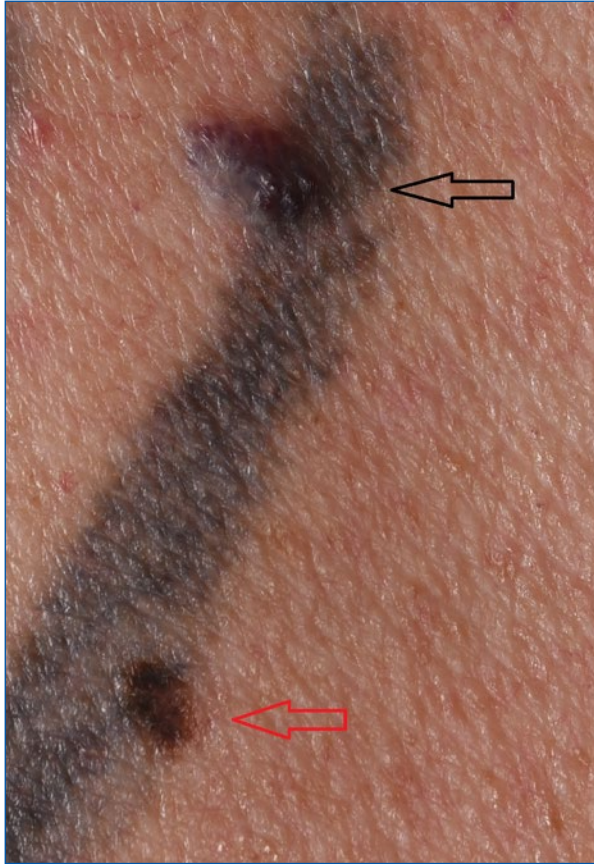

Figure 1. Two pigmented lesions over a black tattoo whose histopathology revealed an hemangioma (black arrow) and a melanoma explanation only in text (not beneath photo).

The patient's past medical history included diabetes mellitus, arterial hypertension, attention deficit hyperactivity disorder, benign prostatic hyperplasia, and fibromyalgia. He also reported a history of melanoma that had been excised from the back about 30 years earlier. The tumor data could no longer be obtained. Furthermore, a superficial spreading melanoma on the right thigh (tumor thickness 0.5 mm, Clark level II, < 1 mitosis/ mm², no nevus association) had been excised in our clinic 2 years prior. Both melanomas had occurred in non-tattooed skin. Follow-ups with a dermatologist had always been unremarkable. As a child, the patient suffered several sunburns.

The two lesions described above were excised under local anesthesia. Histology of the proximal lesion revealed a hemangioma (Fig.1, black arrow), and of the distal lesion (Fig.1, red arrow) a superficial spreading melanoma in the tattoo (Fig. 2 and 3), Clark level II, vertical tumor thickness- Breslow 0.3 mm (pT1a). There was no ulceration or regression.

Discussion

In the present case, tattooing occurred in the history of two malignant melanomas. A third melanoma developed in the black tattoo, which significantly complicated the diagnosis of the third melanoma during tumor follow-up, although we were still able to diagnose and remove the melanoma while it was in stage I. With already two pre-existing melanomas, skin metastasis can also be considered. These often appear to be dark, red, or skin-colored papules or nodules.

We interpret the hemangioma as incidental.

Early detection of malignant melanoma with the aim of excision at low tumor stages is a major goal of dermatologic screening. The rising incidence of melanoma in Germany is currently reported to be 26.5 cases (men) and 25.3 cases (women) per 100,000 inhabitants per year. For tattoos, a prevalence of 14% in Western countries and up to 50% among 25-35-year-olds are reported¹⁻⁵. With the increasing incidence of melanoma coupled with the increasing prevalence of tattoos, a cumulative occurrence of melanoma in tattooed individuals must be expected.

To our knowledge, 36 cases of melanoma in tattoos have been reported in the literature to date. The risk for melanoma development does not appear to be increased per se in tattooed skin^{6,7}. But morphologic evaluation is complicated by the exogenous pigment, resulting in a possible delay in diagnosis⁸. Suspicious nevi can be covered by tattoos so evaluating the nevi is extremely difficult at the clinical and dermoscopic levels. In addition to the generally more difficult assessability, especially dermal signs of malignancy, such as blue or gray veils, can be disguised by a tattoo. Therefore, tattooing must be viewed extremely critically in the presence of multiple and/or atypical nevi syndrome and melanoma in the patient's own and/or family history.

In addition, a thorough dermatologic examination should be performed prior to any laser therapy of a tattoo to avoid triggering changes in nevi or melanoma-specific lesions^{9,10,11}. If laser therapy is specifically desired and indicated, we recommend excising pigmented lesions in the tattoo prior to laser therapy and submitting them to histologic examination. Regarding carcinogenic ingredients of tattooing products, a negative list exists in Germany since 2009, though it has not been established if avoiding these ingredients decreases malignancy risk¹². In addition to the usual provisos, UV protection in the area of tattoos is recommended since UV radiation can potentially alter tattoo ingredients and lighten the tattoo under UV irradiation¹³⁻¹⁵.

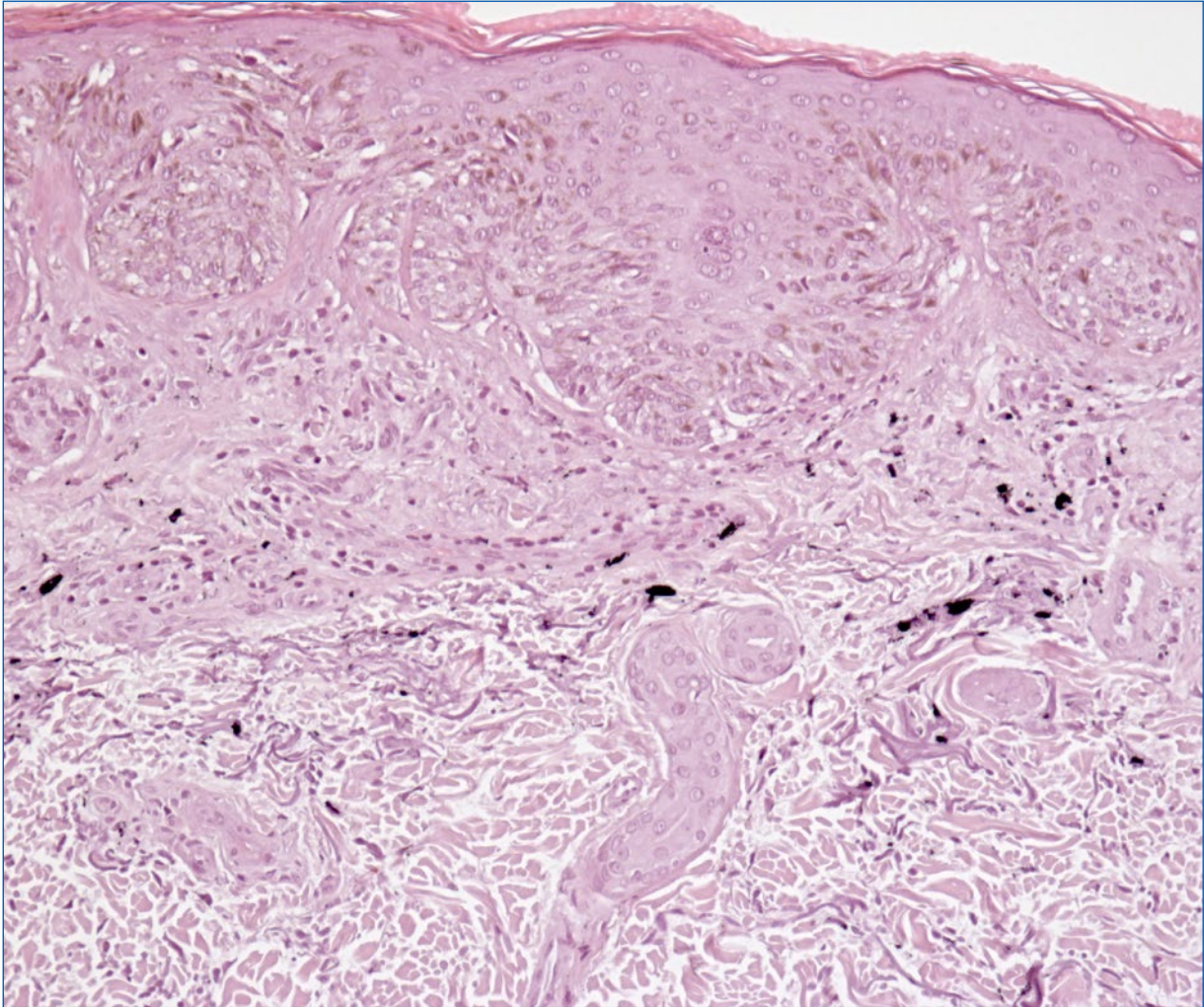


Figure 2. Irregular melanocytic proliferation with formation of nests of atypical melanocytes in the area of the junctional zone and in the adjacent corium. Proliferation of single atypical melanocytes in the basal cell layer with suprabasal storage, discharge into the stratum corneum. Inhomogeneous pigment incontinence and moderate inflammatory infiltrates. In addition, granular to scaly pigment deposits are found in the upper to middle corium. Also, solar elastosis. Diagnosis: superficial spreading melanoma in tattoo, Clark level II, vertical tumor thickness according to Breslow 0.3 mm, (pT1a). No ulceration. No regression. No nevus association.

Summary and conclusion

There should be a low threshold for performing biopsies in suspicious melanocytic lesions within a tattoo, as morphologic malignancy criteria may be obscured by the exogenous pigment.

Tattoos should be very carefully considered in people with multiple nevi syndrome, atypical nevi, and a history of melanoma in self and/or family. No tattoo should be applied in the area of nevi. People with this history should see a dermatologist prior to obtaining a tattoo and obtain regular skin checks after.

Although no correlation between melanoma development and tattooing has been found from the literature available to date, extreme caution should be exercised with tattooing in patients at increased risk for melanoma and prior to laser therapy.

Ethical disclosures

Protection of human and animal subjects. The authors declare that the procedures followed were in accordance with the regulations of the relevant clinical research ethics committee and with those of the Code

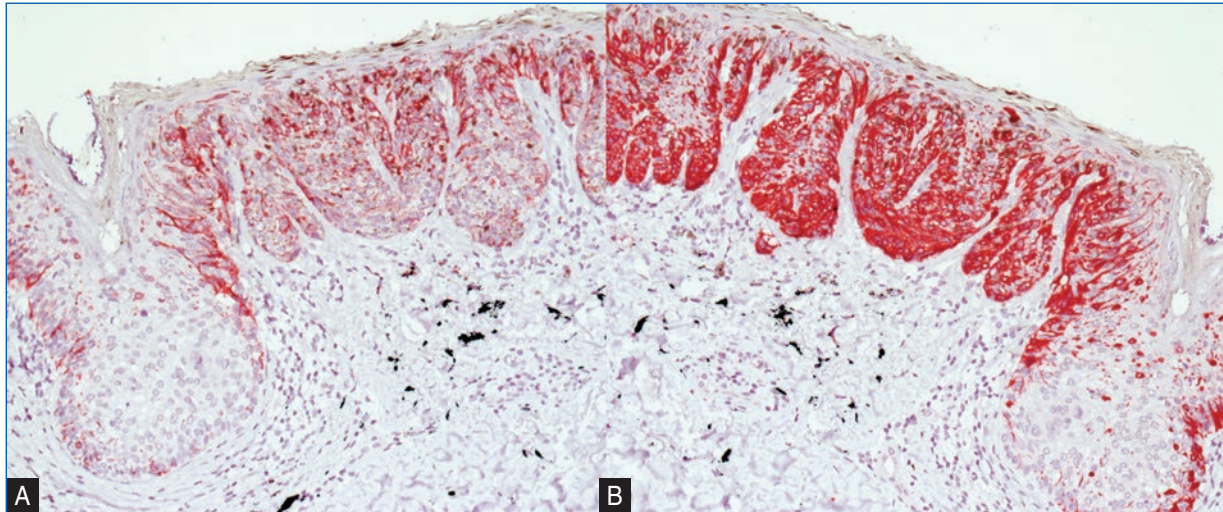


Figure 3. Immunostaining Melan A and HMB45. **A:** immunostaining with monoclonal anti-MART-1/MelanA-antibody (200x) MelanA-Staining marks melanocytes in all layers of the epidermis. **B:** immunostaining with monoclonal anti-HumanMelanomaBlack (HMB45)—antibody (200x) HMB45-Stainings marks premelanosome protein (PMEL) in proliferating melanocytes in all layers of the epidermis.

of Ethics of the World Medical Association (Declaration of Helsinki).

Confidentiality of data. The authors declare that they have followed the protocols of their work center on the publication of patient data.

Right to privacy and informed consent. The authors have obtained the written informed consent of the patients or subjects mentioned in the article. The corresponding author is in possession of this document.

References

- Borkenhagen A. Tattoos in der deutschen Bevölkerung – Prävalenzen, Soziodemografie und Gesundheitsorientierung. Bundesgesundheitsblatt - Gesundheitsforschung - Gesundheitsschutz 2019;62:1077–82. DOI: 10.1007/s00103-019-02999-7
- Heywood W, Patrick K, Smith AMA, Simpson JM, Pitts MK, Richters J, et al. Who gets tattoos? Demographic and behavioral correlates of ever being tattooed in a representative sample of men and women. Ann Epidemiol 2012; 22:51–6.
- Stieger S, Pietschnig J, Kastner C, Voracek M, Swami V. Prevalence and acceptance of tattoos and piercings: a survey of young adults from the southern German-speaking area of Central Europe. Percept Mot Ski 2010;110:1065–74. DOI: 10.1016/j.annepidem.2011.10.005
- Laumann AE, Derick AJ. Tattoos and body piercings in the United States: a national data set. J Am Acad Dermatol 2006;55:413–21. DOI: 10.1016/j.jaad.2006.03.026
- Institute S.B.R., Tattoo statistics <https://www.statisticbrain.com/tattoo-statistics> 2020 Accessed 21st of January 2020
- Kluger N, Debarbieux S, Thomas L. Skin cancers arising in tattoos: coincidental or not? Dermatology 2008;217:219–21. DOI: 10.1159/000143794
- Kluger N, Koljonen V. Tattoos, inks and cancer. Lancet Oncol 2012;13:e161–8. DOI: 10.1016/S1470-2045(11)70340-0
- Joyce CW, Duff G, Mckenna D, Regan PJ. Malignant melanoma arising in red tattoo ink. Arch Plast Surg 2015;42:475–7. DOI: 10.5999/aps.2015.42.4.475
- Kerl H, Raulin C, Landthaler M. Kontroversen in der Dermatologie - Lasertherapie und melanozytäre Nävi. J Dtsch Dermatol Ges 2004;2:681–3.
- Pohl L, Kaiser K, Raulin C. Pitfalls and recommendations in cases of laser removal of decorative tattoos with pigmented lesions: case report and review of the literature. JAMA Dermatol 2013;149:1087–9. DOI: 10.1001/jamadermatol.2013.4901
- Ricci F, Paradisi A, Maier SA, Kovacs M, Podda M, Peris K, Abeni D. Melanoma and tattoos: a case report and review of the literature. Euro J Dermatol 2018;28:50–5. DOI: 10.1684/ejd.2017.3184
- Tätowiermittel-Verordnung vom 13 November 2008(BGBl. I S 2215 die zuletzt durch Artikel 3 der Verordnung vom 26. Januar 2016(BGBl. I S 108) geändert worden ist; https://www.bvl.bund.de/DE/Arbeitsbereiche/03_Verbraucherprodukte/03_AntragstellerUnternehmen/08_Rechtsvorschriften/03_Taetowiermittel/bgs.taetowiermittel_rechtliche_grundlagen_node.html.
- Engel E, Spannberger A, Vasold R, König B, Landthaler M, Bäuml W. Photochemical cleavage of a tattoo pigment by UVB radiation or natural sunlight. J Dtsch Dermatol Ges 2007;5:583–9. DOI: 10.1111/j.1610-0387.2007.06333.x
- Vasold R, Naarmann N, Ulrich H, Fischer D, König B, Landthaler M. et al. Tattoo pigments are cleaved by laser light—the chemical analysis in vitro provide evidence for hazardous compounds. Photochem Photobiol 2004;80:185–90. DOI: 10.1562/2004-05-17-RA-170
- Engel E, Spannberger A, Vasold R, König B, Landthaler M, Bäuml W. Photochemische Spaltung eines Tätowierungspigments durch UV-B-Strahlung oder Sonnenlicht Photochemical cleavage of a tattoo pigment by UV-B radiation or natural sunlight. J Dtsch Dermatol Ges 2007;5:583–90. DOI: 10.1111/j.1610-0387.2007.06333.x