

Hyperpigmentation of the tongue as a clue to the diagnosis of Addison's disease

Hiperpigmentação da língua como uma pista para o diagnóstico da doença de Addison

Hudson D. Rezende^{1,a*}, Carolina Z. Oliveira^{2,b}, Danielle Braga^{3,c}, Aline F. Loures^{1,d}, Letícia Logullo^{1,e}, Sandra L. M. Dinato^{1,f} and Alexandra C. Toled^{4,g}

¹Department of Dermatology, Lusiada University Center, Santos, São Paulo, Brazil; ²Dermatology, Private Practice, Ouro Fino, Minas Gerais, São Paulo, Brazil; ³Endocrinology, Private Practice, Ouro Fino, Minas Gerais, São Paulo, Brazil; ⁴Department of Dermatology, Hospital São Camilo Ipiranga, São Paulo, São Paulo, Brazil

^aORCID: 0000-0002-7039-790X; ^bORCID: 0000-0002-4978-7970; ^cORCID: 0000-0003-2364-9243;

^dORCID: 0000-0002-9718-6782; ^eORCID: 0000-0003-3065-7129; ^fORCID: 0000-0002-4547-0474;

^gORCID: 0000-0002-7241-649X

A 12-year-old girl complaining of fatigue during the last 3 months also reported progressive darkening of the tongue followed by hyperpigmentation of the oral mucosa and the skin. On physical examination, a central macular brown-grey hyperpigmentation of the tongue was noticed (Fig. 1A). Dermoscopy showed irregular pigmentation surrounding the fungiform papillae (Fig. 2). Laboratory examination revealed low glucocorticosteroid serum level (3.6 µg/dL) and high adrenocorticotrophic hormone (ACTH) 1.250 pg/mL, which confirmed the diagnosis of Addison's disease (AD). No other serum parameters were abnormal. After treatment with oral prednisone 7.5 mg/day both the tongue and the skin hyperpigmentation faded in 6 months (Fig. 1B).

Addison's disease is an uncommon condition that is frequently overlooked in clinical practice, yet truly life-threatening¹. Affected individuals may show non-specific signs and symptoms, such as vomiting, unexplained weight loss, fatigue, malaise and generalized hyperpigmentation¹. For patients whose clinical presentation is not complete, pigmentation of the tongue may allow an early diagnosis². Hyperpigmentation results from melanogenesis stimulation due to

increased production of opiomelanocortin³, a prohormone that is the source of biologically active ACTH, and melanocyte-stimulating hormones involved in melanin synthesis^{1,3,4}.

Pigmentation of the oral mucosa has been observed in several different scenarios, such as physiologic conditions, metabolic disorders, use of medications or other exogenous substances^{1,2,5}. Darkening of the tongue may be associated with either melanin deposition or external pigments and is frequently seen among darkly pigmented individuals, in the context of astringent mouthwash abuse, drinking dark tea and other caffeinated drinks, as well as heavy smoking habits^{3,6}.

Any patient with hyperpigmentation of the tongue should be evaluated for systemic medications (e.g., tetracycline, proton pump inhibitors, interferon, phenytoin, and hydroxychloroquine), inherited disorders (Peutz-Jeghers syndrome, von Reckling-hausen's syndrome), hemochromatosis, pernicious anemia and scleroderma^{2,3,7,8}.

According to Studdiford et al., oral cavity hyperpigmentation in AD is typically generalized, with patchy darkening of the inner surface of lips and buccal mucosa and also affects the gingival border and the

***Corresponding author:**

Hudson D. Rezende

E-mail: hudsondutra@gmail.com

2795-501X / © 2022 Portuguese Society of Dermatology and Venereology. Published by Permanyer. This is an open access article under the CC BY-NC-ND license (<http://creativecommons.org/licenses/by-nc-nd/4.0/>).

Received: 10-09-2022

Accepted: 10-10-2022

DOI: 10.24875/PJDV.M22000046

Available online: 09-12-2022

Port J Dermatol and Venereol. 2022;80(4):325-326

www.portuguesejournalofdermatology.com

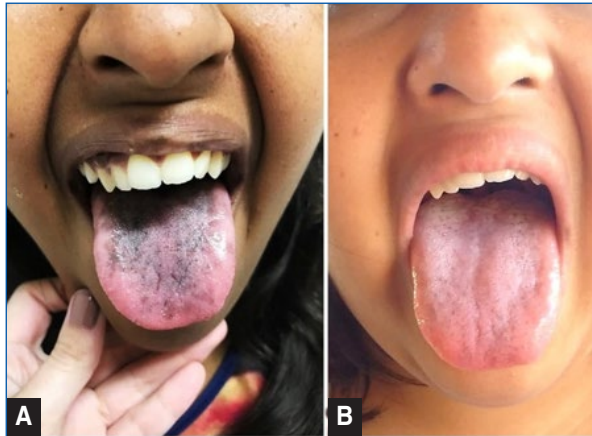

Figure 1. **A:** grayish brown hyperpigmentation of the tongue at first consultation. **B:** after treatment with oral glucocorticoids, both skin and mucosa returned to their original aspects.

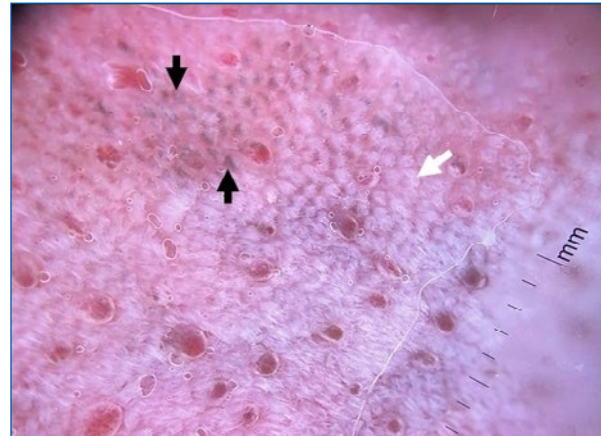


Figure 2. Tongue dermoscopy in Addison's disease: focal spots of brown pigmentation around the lingual papillae on the lateral aspect of the tongue (black arrows). White structures represent the tips of uninvolved papillae (white arrow); handheld dermoscopy.

tongue³, as in the present case. As of yet, there is no data on the dermoscopy of hyperpigmented tongue in AD, but it may represent a complementary tool for such cases, as it may contribute to differentiating between the deposition of melanin and external pigments.

As suggested by Rosebush et al., the combination of fatigue and acquired diffuse pigmentation of the oral cavity has a great practical meaning since the former is virtually present in all patients with AD and the latter is an early, and highly specific feature of the disease². Of note, patients with AD may exhibit isolated oral pigmentation long before skin changes are evident⁹.

Finally, the diagnosis of AD may be tricky, especially when typical and systemic symptoms are not overt. By including AD as a possible diagnosis for mucocutaneous hyperpigmentation, the physician is more likely to recognize the diagnosis of AD earlier.

Ethical disclosures

Protection of human and animal subjects. The authors declare that the procedures followed were in accordance with the regulations of the relevant clinical research ethics committee and with those of the Code

of Ethics of the World Medical Association (Declaration of Helsinki).

Confidentiality of data. The authors declare that they have followed the protocols of their work center on the publication of patient data.

Right to privacy and informed consent. The authors have obtained the written informed consent of the patients or subjects mentioned in the article. The corresponding author is in possession of this document.

References

1. Ten S, New M, Maclaren N. Clinical review 130: Addison's disease 2001. *J Clin Endocrinol Metab.* 2001;86(7):2909–22.
2. Rosebush MS, Briody AN, Cordell KG. Black and brown: non-neoplastic pigmentation of the oral mucosa. *Head Neck Pathol.* 2019;13(1):47–55.
3. Studdiford J, Seecof OM, Traves KP, Valko G. Hyperpigmentation of the tongue and systemic symptoms. *Am Fam Physician.* 2020;101(8):499–501.
4. Figueiredo Gatti R, Medeiros Prohmann C, Araújo Dantas C, Barcelos e Silva L, Marçal Machado T, Rodrigues de Oliveira Mattar F, et al. Hiperpigmentação na doença de Addison: relato de Caso. *J Port Soc Dermatology Venereol.* 2017;75(2):169–72.
5. Ogbechie-Godec OA, Elbuluk N. Melasma: an up-to-date comprehensive review. *Dermatol Ther (Heidelb).* 2017;7(3):305–18.
6. Schwartz RH, Lee T. A two-week-old term baby with a black tongue. *Clin Pediatr (Phila).* 2015;54(11):1110–2.
7. Smogorzewski JM, Armstrong P, Young L. Pigmented fungiform papillae of the tongue in an Indian Male. *Cutis.* 2019;103(3):E16–7.
8. McKenzie AD, McIntosh HW. Hyperpigmentation and pituitary tumor as sequelae of the surgical treatment of Cushing's syndrome. *Am J Surg.* 1965;110(2):135–41.
9. Galioto N, Egeland E. Disorders of the oral cavity. *Fam Med Princ Pract.* 2015;2015:937–45.