

Lingual verrucous lymphangioma circumscriptum: exuberant case in an atypical location

Linfangioma verrucoso circunscrito na língua: caso exuberante em localização atípica

Isabella C. Mendes-Alexandre^{1,a*}, Carolina Souza-de Oliveira^{1,b}, Carla A. Ribeiro-Frota²,
Laísa E. de-Hollanda^{1,c}, Rebeca de-OAM-Martins¹, Vanessa R. Ferreira¹, and Luciana M. dos-Santos³

¹Division of Pediatric Dermatology, Hospital Universitário Getúlio Vargas, Manaus; ²Department of Pediatrics, Albert Einstein Hospital, São Paulo; ³Pediatric Dermatology Department, Hospital Universitário Getúlio Vargas, Manaus, Brasil
ORCID: ^a0000-0002-1460-3705; ^b0009-0005-6410-8357; ^c0000-0003-4240-0777

A 5-year-old girl had confluent, translucent papules on her tongue for 3 years (Fig. 1A and B). Biopsy revealed dilated lymphatic vessels with mononuclear and polymorphonuclear leukocytes (Fig. 1C).

Dermoscopy showed irregular translucent lakes with clear and serosanguineous content (Fig. 2A and B). After the biopsy, macroglossia worsened, and the papules showed necrotic content (Fig. 3A, B and C).

Treatment with triamcinolone acetonide ointment to reduce inflammation and systemic antibiotics was proposed. However, imaging exams to verify the extension of the condition and appropriate clinical treatment were not performed because the patient was lost to follow-up.

Discussion

Lingual lymphangioma circumscriptum (LC) is a benign condition that results from the formation of muscle-lined cisterns, not connected to the lymphatic drainage system, projecting bumps on the skin or mucosa^{1,2}.

Congenital or acquired, LC targets the pediatric population and is diagnosed in children under 2 years

of age in about 90% of cases^{2,3}. The oral cavity is rarely involved, with the more common site being the tongue and, more rarely, palate, buccal mucosa, gingiva, the floor of the mouth, and lips³.

Clinically, LC is asymptomatic and has a good prognosis. However, cases in the head, neck, and oral cavity may be serious due to obstruction of the airways and death².

Lymphangioma circumscriptum (LC) treatment remains challenging because current therapeutic options are limited and have to be adapted according to the size of the lesion, its location and the range of anatomical structures and surroundings that are involved.

Treatment includes excision, cryotherapy, sclerotherapy, laser, radiofrequency, radiotherapy, and local steroids. Also, topical imiquimod with oral propranolol had success⁴.

TOPical sirolimus in linGUal microcystic lymphatic malformatioN [TOPGUN] protocol, ongoing until 2025, is studying the efficacy and safety of topical sirolimus in the case of lymphangioma, which can pave the way into the first-line treatment for lingual microcystic lymphatic malformations⁵.

*Correspondence:

Isabella C. Mendes-Alexandre
E-mail: bellac_mendes@hotmail.com
2795-501X / © 2023 Portuguese Society of Dermatology and Venereology. Published by Permalyer. This is an open access article under the CC BY-NC-ND license (<http://creativecommons.org/licenses/by-nc-nd/4.0/>).

Received: 18-04-2023

Accepted: 04-05-2023
DOI: 10.24875/PJDV.23000031

Available online: 24-05-2023

Port J Dermatol and Venereol. 2023;81(3):221-223
www.portuguesejournalofdermatology.com

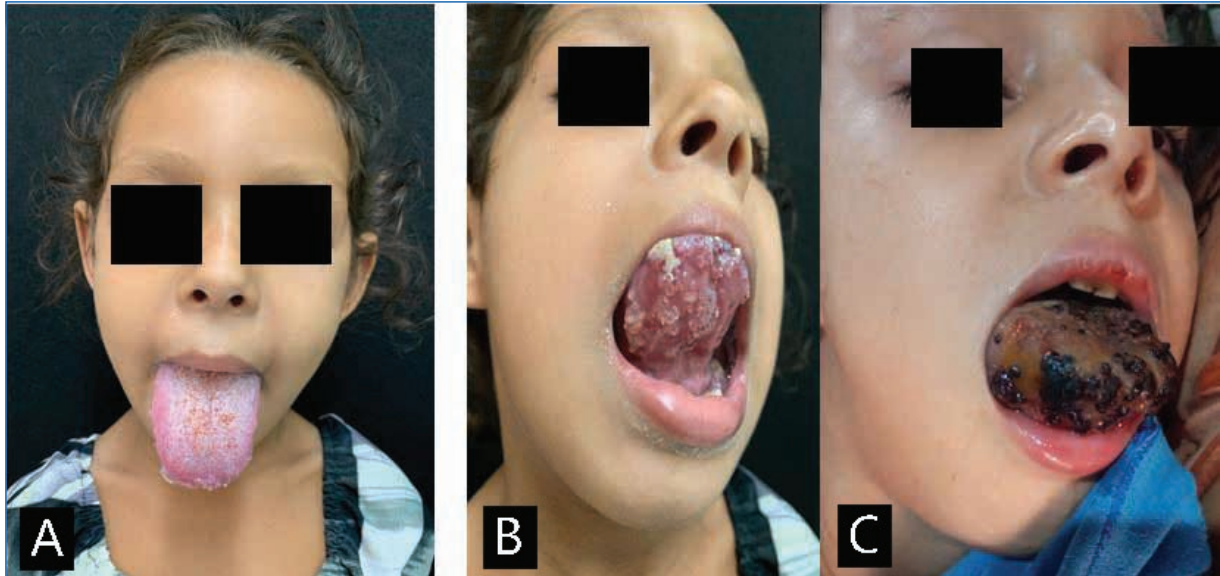


Figure 1. **A:** lesion in the anterior and posterior portion of the tongue before clinical treatment. **B:** multiple cystic lesions with serohemorrhagic content on the lingual dorsum before clinical treatment. **C:** complication 2 days after performing an incisional biopsy for diagnostic purposes.

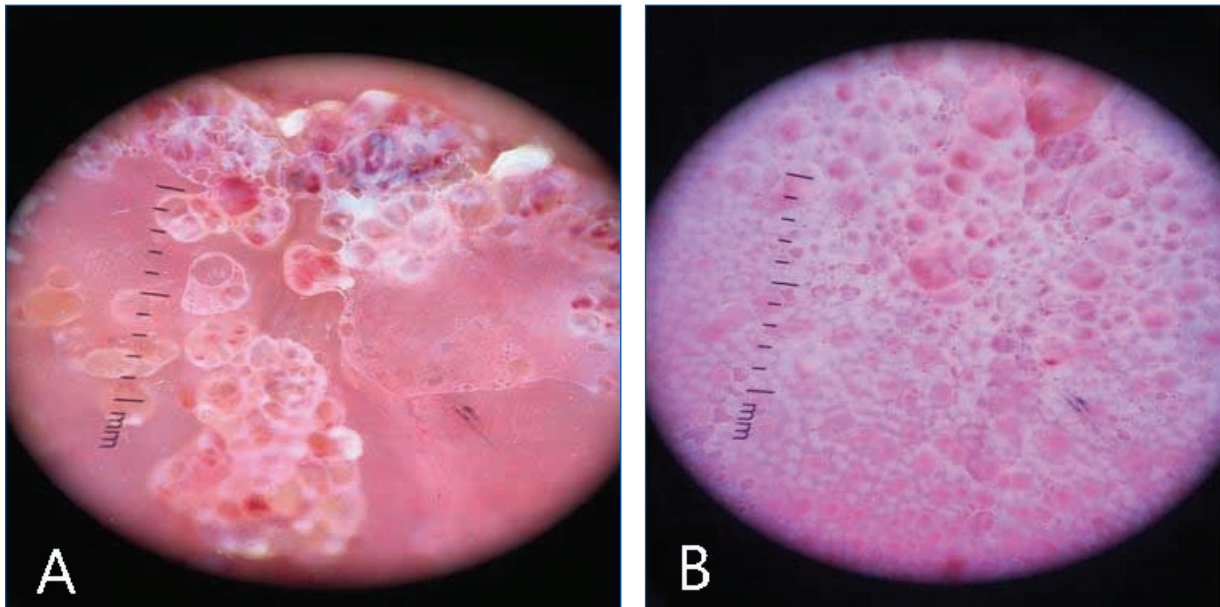


Figure 2. **A:** dermoscopy under polarized light of the dorsum of the tongue revealing papules with serohematic content and intermingled keratotic areas. **B:** papules separated by septum demonstrated by dermoscopy under polarized light.

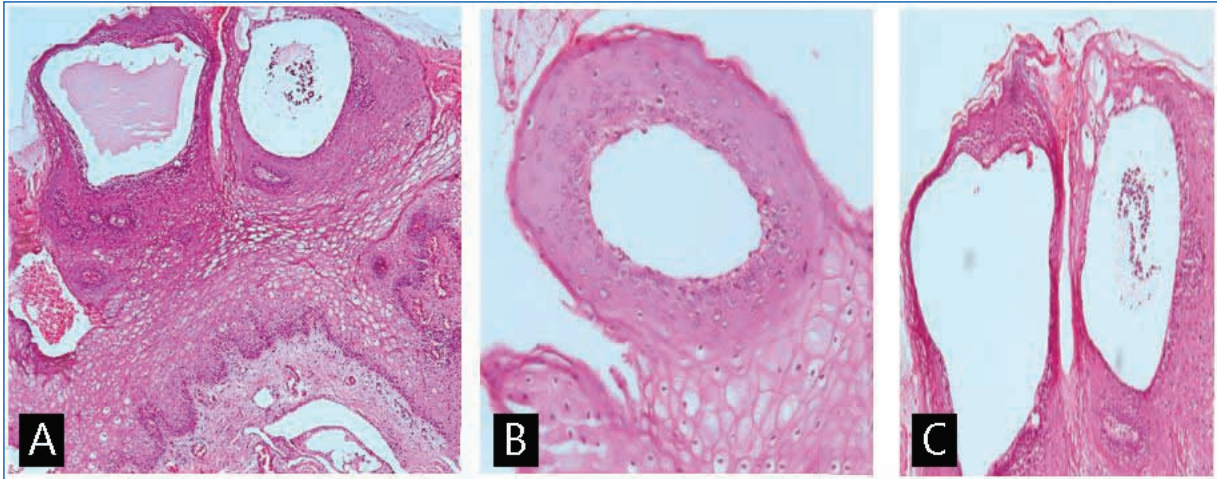


Figure 3. Histopathological features showing dilated lymphatic vessels not connected to the lymphatic network and thin, smooth muscle covered by flattened endothelium, without the presence of a capsule and amorphous lymphatic material inside. **A:** hematoxylin and eosin (H&E), 100× magnification, **B** and **C:** H&E stain, 200× magnification.

Funding

None.

Conflicts of interest

None.

Ethical disclosures

Protection of human and animal subjects. The authors declare that no experiments were performed on humans or animals for this study.

Confidentiality of data. The authors declare that they have followed the protocols of their work center on the publication of patient data.

Right to privacy and informed consent. The authors have obtained the written informed consent

of the patients or subjects mentioned in the article. The corresponding author is in possession of this document.

References

1. Gupta AK, Ellis CN, Gorsulowsky DC. Chronic zosteriform eruption of the lower extremity. *Arch Dermatol.*1988;124:267–8.
2. Magalhães AS, Dias GS, Rocha CRA, Dos Santos JHB, Fernandes TRMO. Linfangioma circunscrito em língua em paciente pediátrico: relato de caso. *Revista de Ensino, Ciência e Inovação em Saúde,* 2021
3. Kurude AA, Phiske MM, Kolekar KK, Nayak CS. Lymphangiomas: rare presentations in oral cavity and scrotum in pediatric age group. *Indian J Dermatol Venereol Leprol.* 2020;86:230.
4. Shah A, Chennareddy S, Sharma S, Sanghvi J, Tassavor B, Lewin JM. Surgical and non-surgical treatment modalities for lymphangioma circumscriptum. *Dermatol Online J.* 2022;28:19
5. Marchand A, Caille A, Gissot V, Giraudeau B, Lengelle C, Bourgoin H. et al. Topical sirolimus solution for lingual microcystic lymphatic malformations in children and adults (TOPGUN): study protocol for a multicenter, randomized, assessor-blinded, controlled, stepped-wedge clinical trial. *Trials.*2022;23:557.