

## Scalp angiosarcoma in elderly patient: case report

### Angiossarcoma de couro cabeludo em paciente idoso: um relato de caso

Oona S. Erdmann<sup>1,a</sup>, Isabelle L. Lemos<sup>1,b</sup>, Karina B. Medeiros<sup>2,c</sup>, Juliana E. Jung<sup>3,d</sup>, and Eduardo M. de-Castro<sup>1,e\*</sup>

<sup>1</sup>Department of Medicine, Faculdades Pequeno Príncipe; <sup>2</sup>Department of Medicine, Hospital Universitário Evangélico Mackenzie; <sup>3</sup>Department of Dermatopathology, Citolab. Curitiba, Paraná, Brazil

<sup>a</sup>ORCID: 0000-0001-8100-7658; <sup>b</sup>ORCID: 0000-0002-9741-1652; <sup>c</sup>ORCID: 0000-0001-8202-6711; <sup>d</sup>ORCID: 0000-0002-1446-7504;

<sup>e</sup>ORCID: 0000-0001-6136-2660

### Abstract

Cutaneous angiosarcomas are rare, aggressive tumors, and represent < 1% of all malignant head and neck neoplasms. Their highest incidence is in elderly men and Caucasians. The importance of reporting cases of this type of tumor is to emphasize it as a differential diagnosis in the elderly. We report a 90-year-old Caucasian male patient with an erythematous and infiltrative scalp tumor. Surgical resection and anatomopathological evaluation, including immunohistochemical studies, diagnosed a high-grade angiosarcoma. Primary cutaneous angiosarcoma is the main form of angiosarcoma, with rapid evolution, affecting mainly the scalp and face. It presents with varied morphologies, irregular growth, and spontaneous bleeding. Microscopic findings include infiltrating and anastomosing vascular channels lined by atypical endothelial cells, as well as solid growth in high-grade tumors. The prognosis is poor, usually related to the patient's age, lesion site, and disease stage. The variable microscopy may mimic other neoplasms, and a wide spectrum of diseases should be considered in the differential diagnosis.

**Keywords**—Angiossarcoma. Case report. Immunohistochemistry. Skin.

### Resumo

Angiossarcomas cutâneos são tumores raros e agressivos, e representam menos de 1% de todas as neoplasias malignas de cabeça e pescoço. Sua maior incidência é em homens idosos e caucasianos. A importância de relatar casos desse tipo de tumor está em enfatizá-lo com um diagnóstico diferencial em idosos. Relata-se paciente masculino, 90 anos, caucasiano, com tumorações eritematosas e infiltrativas do couro cabeludo. Após ressecção cirúrgica e avaliação anatomopatológica, incluindo estudo imunoistoquímico, diagnosticou-se angiossarcoma de alto grau. O angiossarcoma cutâneo primário é a principal forma de angiossarcoma, possui rápida evolução e acomete principalmente couro cabeludo e face. À macroscopia, apresentam morfologia variada, crescimento irregular e sangramento espontâneo. Achados microscópicos incluem canais vasculares anastomosados e infiltrativos, revestidos por células endoteliais atípicas, bem como crescimento sólido em tumores de alto grau. O prognóstico é mau, geralmente relacionado à idade do paciente, local da lesão e estágio da doença. A microscopia variável pode mimetizar outras neoplasias, devendo-se considerar amplo espectro de doenças no diagnóstico diferencial.

**Palavras-chave:** Angiossarcoma. Relato de caso. Imuno-histoquímica. Pele.

#### \*Corresponding author:

Eduardo M. de-Castro  
E-mail: medmoca@gmail.com

Received: 03-09-2022

Accepted: 25-11-2022  
DOI: 10.24875/PJDV.22000016

Available online: 01-02-2023

Port J Dermatol and Venereol. 2023;81(1):57-61  
[www.portuguesejournalofdermatology.com](http://www.portuguesejournalofdermatology.com)

2795-501X / © 2023 Portuguese Society of Dermatology and Venereology. Published by Permanyer. This is an open access article under the CC BY-NC-ND license (<http://creativecommons.org/licenses/by-nc-nd/4.0/>).

## Introduction

Cutaneous angiosarcomas are rare and quite aggressive tumors that originate from the cells of the blood or lymphatic vascular endothelium. The incidence is higher in elderly men and Caucasians<sup>1</sup>. Risk factors include radiation, chemical exposure to arsenic, and previous history of chronic lymphedema<sup>2</sup>.

Epidemiologically, they represent less than 1% of all malignant neoplasms in the head and neck. In addition, angiosarcomas are described in the literature in other anatomical regions, such as the liver, spleen, bones, and heart<sup>1</sup>.

Regarding morphology, they can present as a papule, macula, plaque, or nodule of imprecise limits and variable extension, and hemorrhagic or necrotizing surface. The possibility of resection, presence of metastases, degree of differentiation, and lesion extension are very important prognostic factors<sup>3</sup>.

We report a case of angiosarcoma of the scalp, emphasizing the importance of considering it as one of the differential diagnoses in elderly patients since early diagnosis allows an extremely favorable outcome.

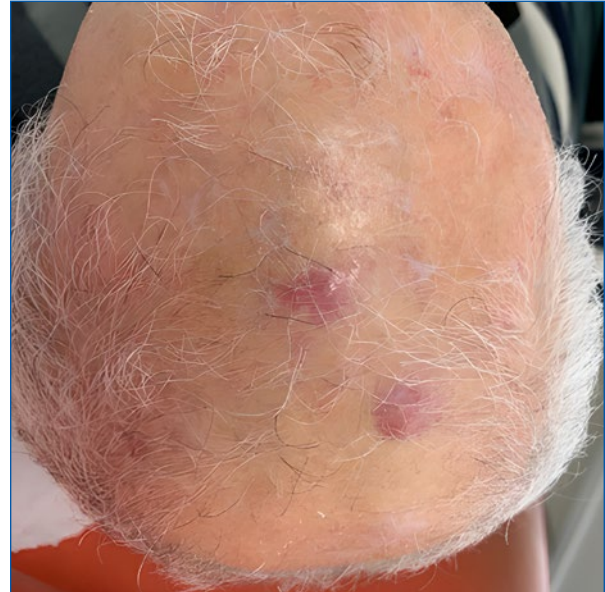Therefore, the objective of this case report is to describe the appearance of angiosarcoma on the scalp of a patient who was being followed up after the excision of nasal basal cell carcinoma. It also aims to perform a literature review on angiosarcoma, approaching its pathophysiology, epidemiological aspects, clinical manifestations, both typical and atypical, and treatment.

## Clinical case

A 90-year-old Caucasian male patient, with a history of controlled asthma, presented to a medical consult in October 2020 for the investigation of a rapidly growing lesion on the left nasal wing, measuring 2 cm. Biopsy confirmed basal cell carcinoma. The tumor was surgically removed, and the area was reconstructed. At the time, his medications included turmeric, paracetamol, vitamin B complex (B1, B6, B12), vitamin D, amlodipine, and inhaling fluticasone.

In July 2021, he returned for a follow-up and an investigation of new skin lesions on the scalp. There were changes to his pharmacological therapy, with the removal of the vitamin B complex and turmeric, and the addition of apixaban. Physical examination revealed the presence of two erythematous and infiltrative tumors, named “larger” and “smaller” lesions (Figure 1).

Incisional biopsies of the lesions suggested a poorly differentiated neoplasm infiltrating the dermis.

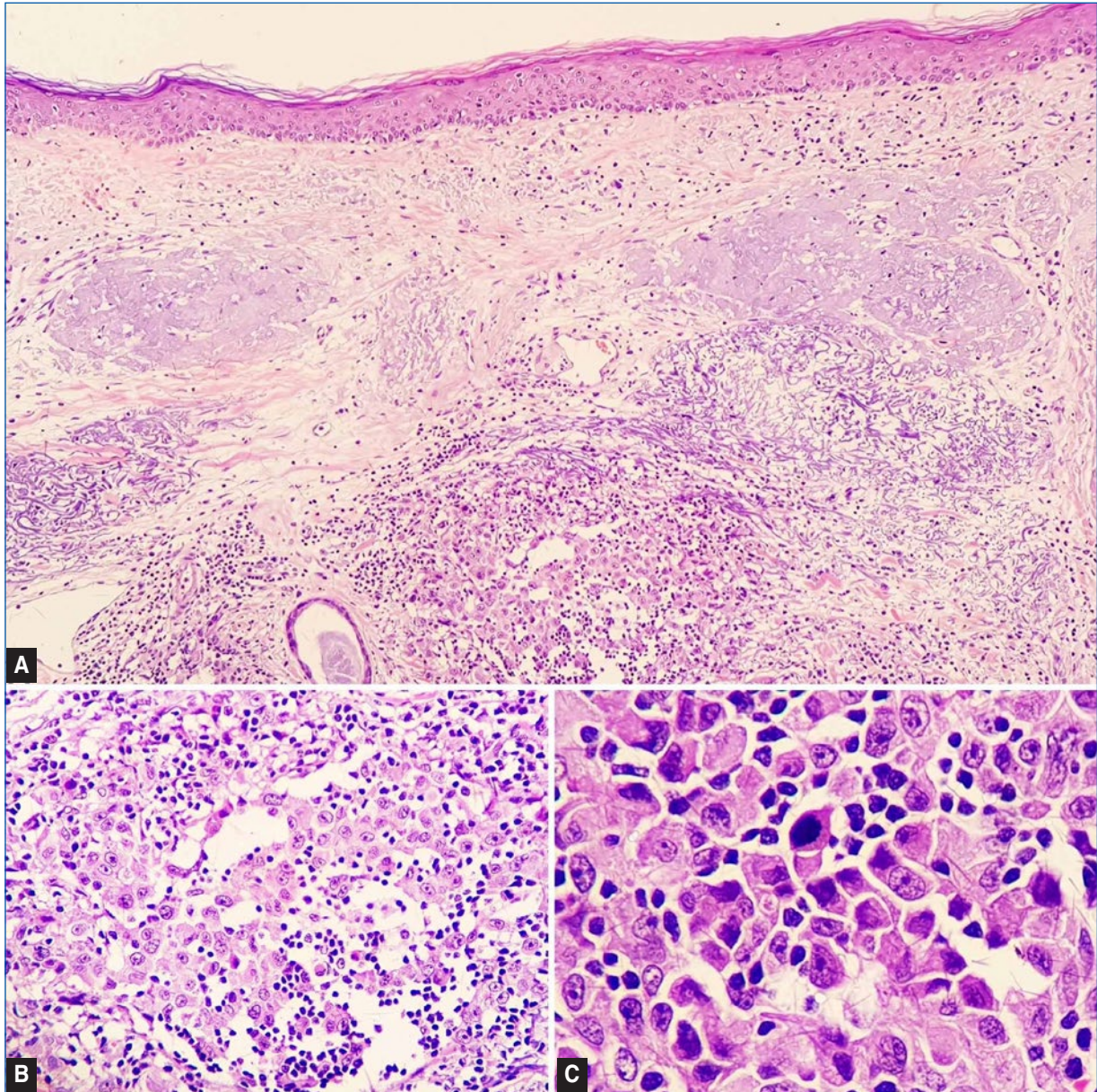


**Figure 1.** Erythematous lesions on the scalp measuring the largest 3.1 × 2.0 cm and the smallest 2.0 × 1.7 cm.

The patient was then submitted to surgical resection of the lesions, and reconstruction was performed with a left iliac fossa skin graft and rotation flap, and 2nd intention healing area.

Gross anatomopathological evaluation of the surgical specimen showed two contiguous, whitish, elevated, and ill-defined lesions, with 3.1 × 2.0 cm with a maximum thickness of 0.6 cm, and 2.0 × 1.7 cm with a maximum thickness of 0.4 cm. Both were 0.5 cm distant from the radial margin. Microscopic examination revealed a poorly differentiated invasive neoplasm involving the dermis and muscle fascia. The architectural pattern was solid, and there were numerous mitotic figures (Figure 2) and moderate peritumoral lymphocytic infiltrate. Deep and radial surgical margins were clear. The immunohistochemical study, including antibodies for the differential diagnosis between carcinoma, melanoma, and angiosarcoma, confirmed the vascular lineage markers cluster of differentiation 31 (CD31), CD34, D2-40, and friend leukemia integration 1 transcription factor (FLI-1) (Figure 3). Other markers for epithelial and melanocytic lineages were negative. The final diagnosis was high-grade angiosarcoma.

In the immediate postoperative period, the patient presented partial necrosis of the graft. However, approximately one month after the removal of the lesions, the patient was reassessed and the surgical wound was in the process of healing, with no signs of necrosis or infection. The patient underwent ten sessions of adjuvant radiotherapy and was discharged



**Figures 2.** Histopathological characteristics of the neoplasm. **A:** small magnification, showing the neoplasm occupying dermis (40 $\times$ , H&E). **B:** atypical cells with permeating lymphocytes (100 $\times$ , H&E). **C:** detail showing nuclear pleomorphism and mitotic figures (400 $\times$ , H&E).

(Figure 4). By the end of the treatment, the patient developed metastatic lesions in the trunk and died soon after.

## Discussion

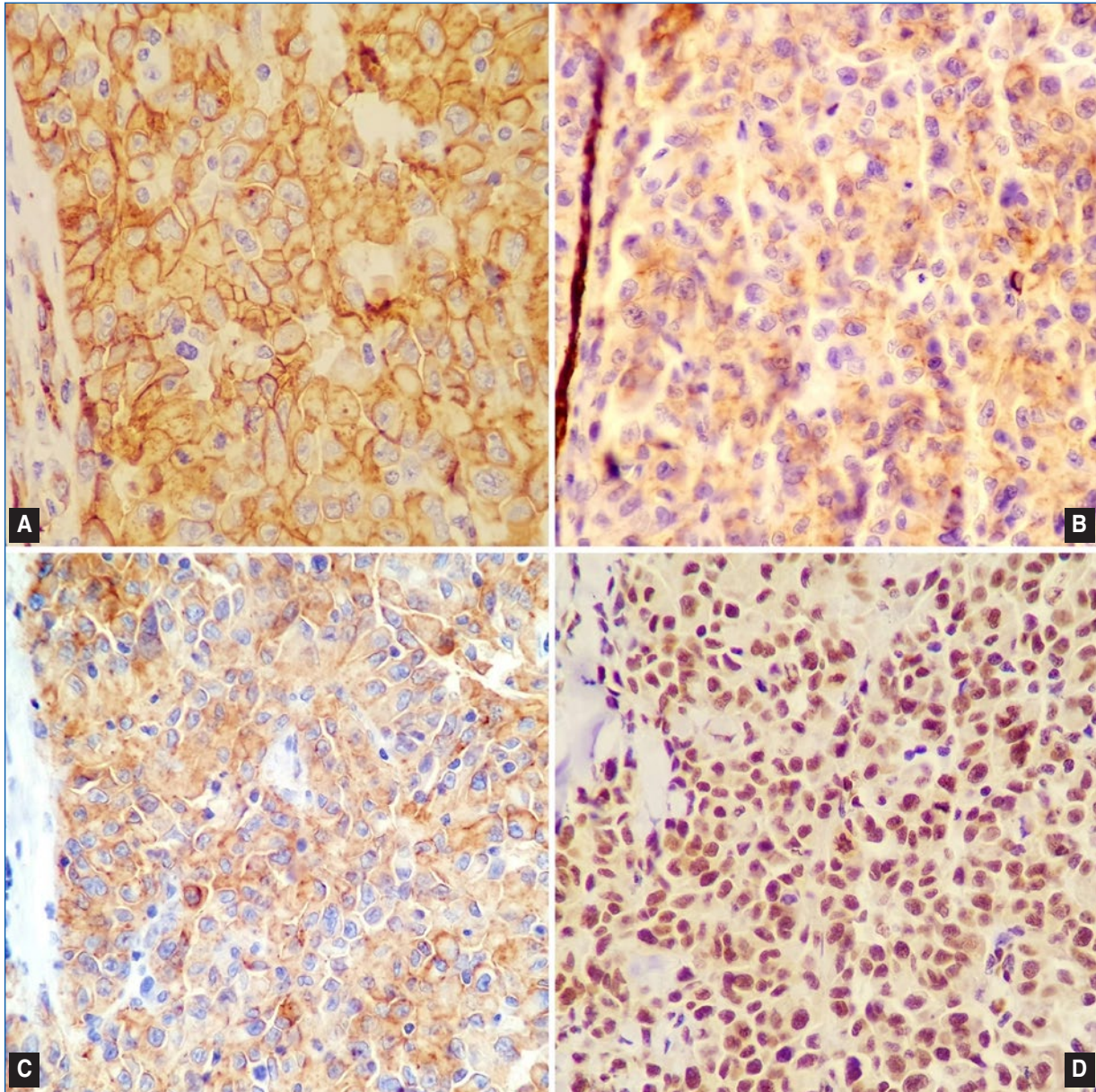
Primary cutaneous angiosarcoma is the main form of angiosarcoma, which evolves rapidly, and the main affected sites are the scalp and face, the latter being considered the most aggressive topography<sup>4</sup>.

Epidemiologically, in angiosarcomas overall, there is no significant prevalence difference between men and

women<sup>4</sup>, however, when located on the scalp, the prevalence is higher in elderly Caucasian men, as seen in the reported case<sup>5</sup>.

Although still much debated, the main hypothesis for the origin of this neoplasm is the endothelium of smaller blood or lymphatic vessels or their progenitor cells<sup>6</sup>. Rarely do these tumors arise from large vessels<sup>5</sup>. Radiotherapy and chronic lymphedema are known risk factors<sup>6</sup>.

Macroscopically, the lesion is poorly delimited, and can present in different morphologies-areas of subcutaneous hematoma, bluish macules, peripheral



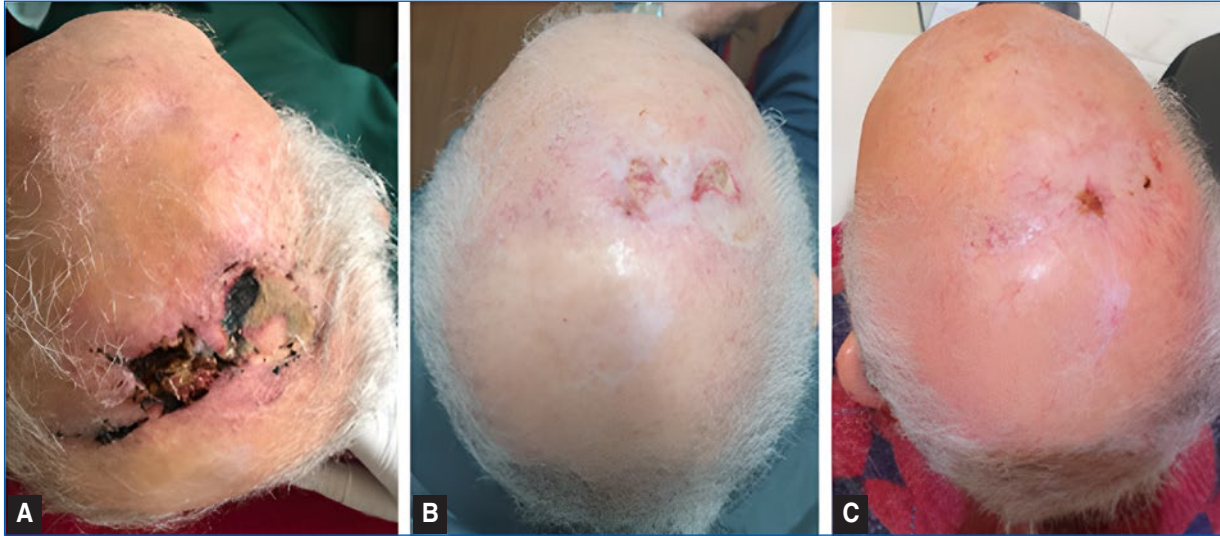
**Figures 3.** Immunohistochemical characteristics of the neoplasm (100 $\times$ , IHC). Positivity in neoplastic cells for the markers. **A:** CD34. **B:** CD31. **C:** D2-40. **D:** FLI-1.

erythematous ring and satellite nodules, as reddish, raised papules<sup>7</sup> or as flat, infiltrative plaques<sup>5</sup>. In more advanced stages, lesions can be elevated, nodular, and ulcerated<sup>5</sup>. It has irregular growth and may acquire a multicentric appearance, containing bluish plaques, and nodules within<sup>4</sup>. It tends to bleed spontaneously or due to minimal trauma<sup>4,5</sup>.

Microscopically, they are poorly differentiated and can compromise the dermis and soft tissues<sup>5</sup>. From the morphological point of view, they can be classified as low or high-grade lesions. Low-grade angiosarcomas are described as neoplasms of atypical endothelial

cells arranged in single or multiple layers, while high-grade angiosarcomas are described as neoplasms of undifferentiated and pleomorphic cells, with disorganized architecture, high mitotic index, and foci of hemorrhage and necrosis<sup>4,5</sup>. The final diagnosis requires immunohistochemistry studies, especially in high-grade neoplasia, with positivity for endothelial markers such as D2-40, CD31, CD34, and FLI-1<sup>8</sup>, as in the reported case<sup>4,9</sup>.

The prognosis of the neoplasm is poor<sup>3,5,6</sup>. The survival rate is directly associated with patient age, lesion site, and disease stage<sup>7</sup>. Factors favoring a better prognosis



**Figures 4.** Postoperative evolution. **A:** partial necrosis of the skin graft from the left iliac fossa. **B:** graft healing in the late postoperative period. **C:** after adjuvant radiotherapy.

would be lesions in smaller quantity and size, younger patients, and clear surgical margins<sup>5</sup>.

The most effective form of treatment is surgical resection, despite the high recurrence rate and difficulty in achieving free surgical margins<sup>4,5</sup>. Multimodal therapy requires an assessment of the age and the general clinical condition of the patient. Chemotherapy is used in patients with incomplete surgical resection or with distant metastasis, such as lungs, liver, spleen, and cervical lymph nodes<sup>4,6,10</sup>.

Radiotherapy is also a viable treatment option, and patients who received it as a form of therapy had a median survival rate four times higher when compared to those who did not use this approach<sup>5</sup>.

The combination of surgery and radiotherapy can be associated with a better prognosis when combined with the previously mentioned factors, but only if applied to lesions smaller than 5 cm in diameter<sup>5</sup>.

Scalp cutaneous angiosarcoma is the most aggressive form of this neoplasm, affecting mostly elderly Caucasian men. Its main treatment is surgery, which can be complemented with adjuvant chemotherapy or radiotherapy, or both. Despite its rarity, angiosarcoma cannot be ignored as a potential diagnosis since the microscopy is very variable and may mimic other neoplasms such as other sarcomas, melanoma, and carcinomas, which highlights the importance of considering a broad spectrum in the differential diagnosis.

## Funding

None.

## Conflicts of interest

None.

## Ethical disclosures

**Protection of human and animal subjects.** The authors declare that no experiments were performed on humans or animals for this study.

**Confidentiality of data.** The authors declare that they have followed the protocols of their work center on the publication of patient data.

**Right to privacy and informed consent.** The authors have obtained the written informed consent of the patients or subjects mentioned in the article. The corresponding author is in possession of this document.

## References

- Mullins B, Hackman T. Angiosarcoma of the head and neck. *Int Arch Otorhinolaryngol.* 2015;19:191–95.
- Vinay K, Abbas A, Aster J, Robbins & Cotran Pathologic Basis of Disease. 10th Edition. Philadelphia. Elsevier. 2020.
- Grundahl JEH, Hallermann C, Schulze HJ, Klein M, Wermker K. Cutaneous angiosarcoma of head and neck: a new predictive score for loco-regional metastasis. *Transl Oncol.* 2015;8:169–75.
- Oley MC, Oley MH, Durry MF, Kepel EM, Farukh M. Cutaneous angiosarcoma: a case report. *International Journal of Surgery Case Reports.* 2021;88:1–5.
- Pawlik TM, Paulino AF, McGinn CJ, Baker LH, Cohen DS, Morris JS, et al. Cutaneous angiosarcoma of the scalp: a multidisciplinary approach. *Cancer.* 2003;98:1716–26.
- Zhang Y, Yan Y, Zhu M, Chen C, Lu N, Qi F, et al. Clinical outcomes in primary scalp angiosarcoma. *Oncol Lett.* 2019;18:5091–6.
- Bhatti Z, Bhatti R, Brangman S, Whiting K, Dharamoon A. Extensive cutaneous scalp angiosarcoma. *Hindawi.* 2018;2018:1–3.
- Chugh AP, Gandhoke CS, Mohite AG, Khedkar BV. Primary angiosarcoma of the skull: a rare case report. *Surg Neurol Int.* 2014;92:1–4.
- Dabbs D. *Diagnostic Immunohistochemistry: theranostic and genomic applications.* Rio de Janeiro, Brazil. Elsevier. 2018.
- Vora R, Anjaneyan G, Gupta R. Cutaneous angiosarcoma of head and neck. *Indian J Dermatol.* 2014;59:632.