

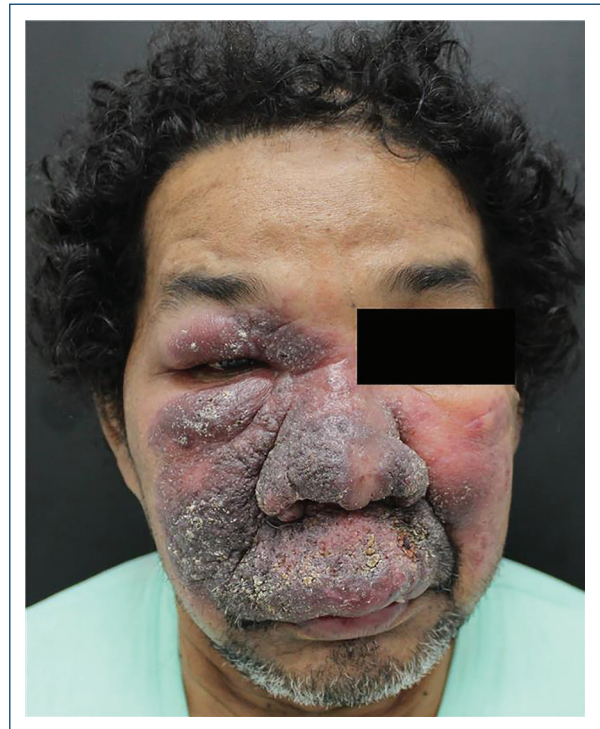## Exuberant, infiltrative, and disfiguring form of mucocutaneous leishmaniasis

### *Forma exuberante, infiltrativa e desfigurante de leishmaniose mucocutânea*

Leandro de Oliveira-Bispo<sup>1</sup>, Laís Büttner-Sartor<sup>1</sup>, Gabriella Di Giunta-Funchal<sup>2</sup>,  
Barbara Hartung-Lovato<sup>1,3</sup>, and Gustavo Moreira-Amorim<sup>1,3\*</sup>

<sup>1</sup>Sector of Dermatology, Santa Teresa Hospital, Santa Catarina State Secretary for Health, São Pedro de Alcântara; <sup>2</sup>Polydoro Ernani de São Thiago University Hospital, Santa Catarina Federal University, Florianópolis; <sup>3</sup>Faculty of Medicine, South Santa Catarina University, Palhoça. Santa Catarina, Brazil

We report a case of a 54-year-old male with mucocutaneous leishmaniasis, confirmed by press imprinting smear (positive for amastigote forms). He was originally from an endemic region for leishmaniasis americana in northern Brazil and had a history, from 10 years ago, of a single ulcerated lesion on his upper arm that cured spontaneously. In the last 6 months, he started with throat pruritus that progressed into verrucous violet plaques covering more than 50% of his face (Fig. 1). We performed a skin biopsy for imprinting, cultures, and histopathology, that identified amastigotes (Figs. 2 and 3). Cutaneous leishmaniasis is a noncontagious infectious disease endemic in some regions of Brazil that can affect skin and mucous membranes<sup>1</sup>. It is transmitted by different species of mosquitoes that carry the promastigote form of leishmania parasites in their gut and inoculate them into the skin of the human host. These promastigotes are phagocytosed and transform into amastigotes and multiply themselves. Initially, there is usually a single painless ulcer with framed borders that heals itself spontaneously<sup>1,2</sup>. Depending on the parasite and the immune response of the host, years after the first lesion disappears, the



**Figure 1.** Violet verrucous plaques, on an erythematous base and diffuse edema of the base.

**\*Correspondence:**

Gustavo Moreira-Amorim

E-mail: [gustavomoreiraamorim@hotmail.com](mailto:gustavomoreiraamorim@hotmail.com)

2795-501X / © 2024 Portuguese Society of Dermatology and Venereology. Published by Permanyer. This is an open access article under the CC BY-NC-ND license (<http://creativecommons.org/licenses/by-nc-nd/4.0/>).

**Received:** 03-09-2024

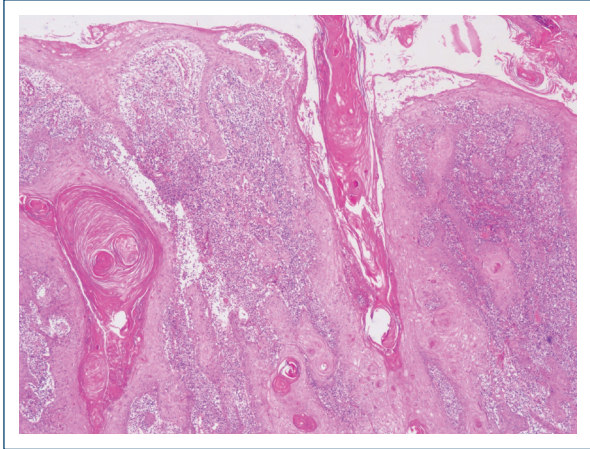
**Accepted:** 24-09-2024

**DOI:** 10.24875/PJDV.24000073

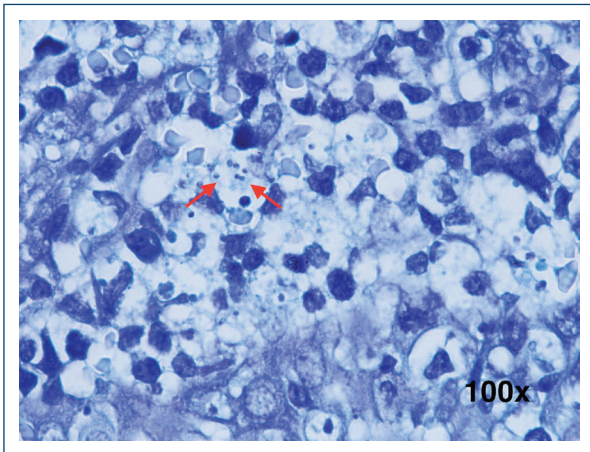
Available online: 26-02-2025

*Port J Dermatol and Venereol.* 2025;83(2):149-150

[www.portuguesejournalofdermatology.com](http://www.portuguesejournalofdermatology.com)



**Figure 2.** Hematoxylin and Eosin (H&E) staining, 10x. Pseudocarcinomatous epithelial hyperplasia, with dense, chronic inflammatory infiltrate, extending to the deep reticular dermis.



**Figure 3.** Giemsa staining, 100x. The arrows point to the presence of amastigote forms inside the histiocytes.

disease might recur. The mucocutaneous form of the disease is usually caused by an intense immunopathological response and is more prevalent in immunocompromised patients<sup>3</sup>. It can present as plaques or verrucous lesions and may cause destruction of the

lips, palate and nasal septum. Therefore, differential diagnoses should include sporotrichosis, leprosy, deep mycosis and even squamous cell carcinoma<sup>1-3</sup>. Patient failed treatment with pentavalent antimony, requiring a full course of liposomal amphotericin B, with apparent clinical cure after 6 months. This case highlights the importance of recognizing the clinical aspects in early stages of the disease to avoid permanent sequelae.

### Funding

None.

### Conflicts of interest

None.

### Ethical considerations

**Protection of humans and animals.** The authors declare that no experiments involving humans or animals were conducted for this research.

**Confidentiality, informed consent, and ethical approval.** The authors have followed their institution's confidentiality protocols, obtained informed consent from patients, and received approval from the Ethics Committee. The SAGER guidelines were followed according to the nature of the study.

**Declaration on the use of artificial intelligence.** The authors declare that no generative artificial intelligence was used in the writing of this manuscript.

### References

1. de Vries HJC, Schallig HD. Cutaneous leishmaniasis: A 2022 updated narrative review into diagnosis and management developments. *Am J Clin Dermatol.* 2022;23(6):823-40.
2. Gurel MS, Tekin B, Uzun S. Cutaneous leishmaniasis: A great imitator. *Clin Dermatol.* 2020;38(2):140-51.
3. Reithinger R, Dujardin JC, Louzir H, Pirmez C, Alexander B, Brooker S. Cutaneous leishmaniasis. *Lancet Infect Dis.* 2007;7(9):581-96.