

Basal cell carcinoma: clinical and digital dermoscopy combined with color Doppler skin ultrasound

Carcinoma basocelular: clínica e dermatoscopia digital combinada com ecografia cutânea com padrão doppler colorido

César Martins 

Unit of Dermatology, Unidade Local de Saúde, Médio Tejo, Portugal

The integration of digital dermoscopy with Doppler ultrasound significantly improved diagnostic accuracy. A high-frequency probe allows evaluation of superficial blood vessels being suitable for superficial skin lesions and detailed assessment of cutaneous vascularization. This combined method not only facilitated the identification of vascular patterns associated with each type of lesion but also provided a comprehensive view of the lesion as a whole.

A 67-year-old male, phototype 2, Dutch patient came to the clinic with a nodular lesion on his back, approximately 10 mm in diameter, erythematous with well-defined contours (Fig. 1). The clinical history reported no significant sun exposure, but the patient had another pigmented lesion on his left arm.

Digital dermoscopy revealed the presence of irregular telangiectasias and blue dots (Fig. 2).

A GE ultrasound machine with a high-frequency probe (20 Hz) with color Doppler revealed thickening at the level of the dermis and a color Doppler pattern showing increased vascularization with blood flow around the lesion (Fig. 3).

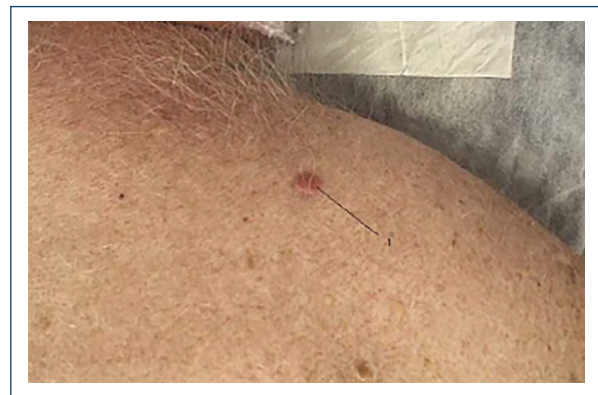

Figure 1. Nodular lesion on the back.

Histopathological analysis revealed nests of basaloid cells in the epidermis with peripheral palisading.

Based on the clinical, dermoscopic, and echographic assessments, the diagnosis of basal cell carcinoma was made and histologically confirmed^{1,2}.

The patient was treated according to the National Comprehensive Cancer Network guidelines, with conventional surgery with a safety margin of 4 mm³.

Correspondence:

César Martins

E-mail: wmed.medicos@sapo.pt

2795-501X / © 2024 Portuguese Society of Dermatology and Venereology. Published by Permanyer. This is an open access article under the CC BY-NC-ND license (<http://creativecommons.org/licenses/by-nc-nd/4.0/>).

Received: 14-10-2024

Accepted: 06-11-2024

DOI: 10.24875/PJDV.24000084

Available online: 12-12-2025

Port J Dermatol and Venereol. 2025;83(4):276-277

www.portuguesejournalofdermatology.com

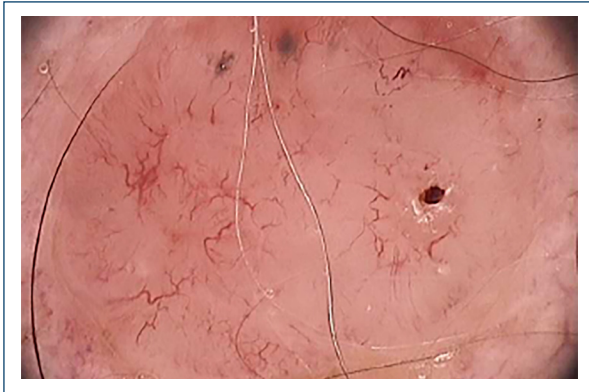

Figure 2. Digital dermoscopy image.

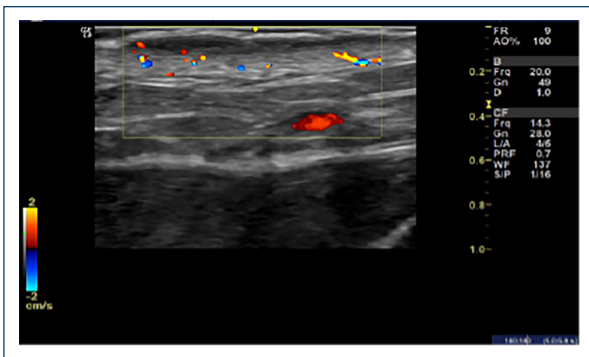


Figure 3. Cutaneous ultrasound using a high-frequency probe (20 Hz) with colour Doppler.

Funding

None.

Conflicts of interest

None.

Ethical considerations

Protection of humans and animals. The authors declare that no experiments involving humans or animals were conducted for this research.

Confidentiality, informed consent, and ethical approval. The authors have obtained approval from the Ethics Committee for the analysis of routinely obtained and anonymized clinical data, so informed consent was not necessary. Relevant guidelines were followed.

Declaration on the use of artificial intelligence. The authors declare that no generative artificial intelligence was used in the writing of this manuscript.

References

1. Lallas A, Apalla Z, Ioannides D, Argenziano G, Castagnetti F, Moscarella E, et al. Dermoscopy in the diagnosis and management of basal cell carcinoma. *Future Oncol.* 2015;11(22):2975-2984.
2. Wortsman X. Sonography of facial cutaneous basal cell carcinoma: a first-line imaging technique. *J Ultrasound Med.* 2013;32(4):567-72.
3. Kauvar AN, Cronin T Jr, Roenigk R, Hruza G, Bennett R. Consensus for nonmelanoma skin cancer treatment: basal cell carcinoma, including a cost analysis of treatment methods. *Dermatol Surg.* 2015;41(5):550-71.