

Transient hyperpigmentation of the distal phalanges in a fair-skinned infant

Hiperpigmentação transitória das falanges distais num lactente caucasiano

Mélissa M. de Carvalho^{1*}, Cristina Amaro², and Alexandre Miroux Catarino¹

¹Serviço de Dermatovenereologia. Unidade Local de Saúde de Lisboa Ocidental; ²Serviço de Dermatovenereologia. Hospital de Cascais. Lisbon, Portugal

We present a 2-month-old Caucasian infant (photo-type II) referred for evaluation of bilateral, symmetrical, well-demarcated brownish-orange macules located on the dorsal surface of the distal phalanges (Fig. 1). No other areas of hyperpigmentation or nail abnormalities were observed. Clinical follow-up demonstrated spontaneous and complete resolution by 12 months of age (Fig. 2).

Transient hyperpigmentation of the distal phalanges is a benign cutaneous condition, described mainly in newborns with darker phototypes and uncommon in children with lighter phototypes¹⁻⁴. These pigmentary changes represent a physiological variant whose etiology remains incompletely understood and may be related to transient hormonal changes during the neonatal period¹⁻³. The differential diagnosis includes potentially serious conditions, such as congenital adrenal hyperplasia and

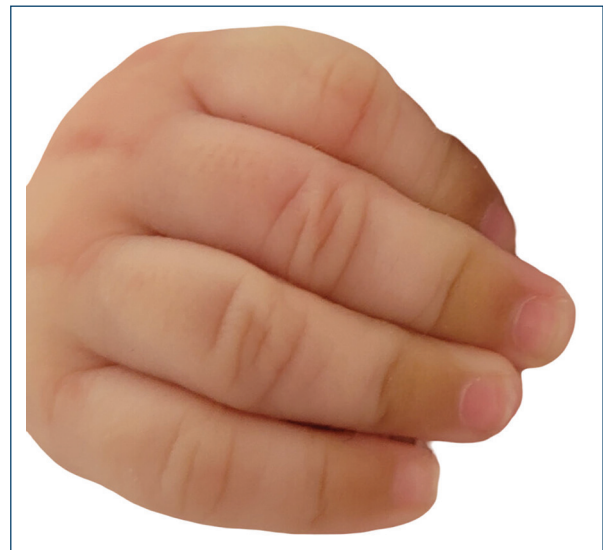

Figura 1. Brownish-orange, well-defined macules on the dorsal surface of the distal phalanges.

***Correspondence:**

Mélissa M. de Carvalho

E-mail: mm.decarvalho@outlook.com

2795-501X / © 2026 Portuguese Society of Dermatology and Venereology. Published by Permanyer. This is an open access article under the CC BY-NC-ND license (<http://creativecommons.org/licenses/by-nc-nd/4.0/>).

Received: 16-01-2026

Accepted: 23-01-2026

DOI: 10.24875/PJDV.26000007

Available online: 26-02-2026

Port J Dermatol and Venereol. (ahead of print)

www.portuguesejournalofdermatology.com

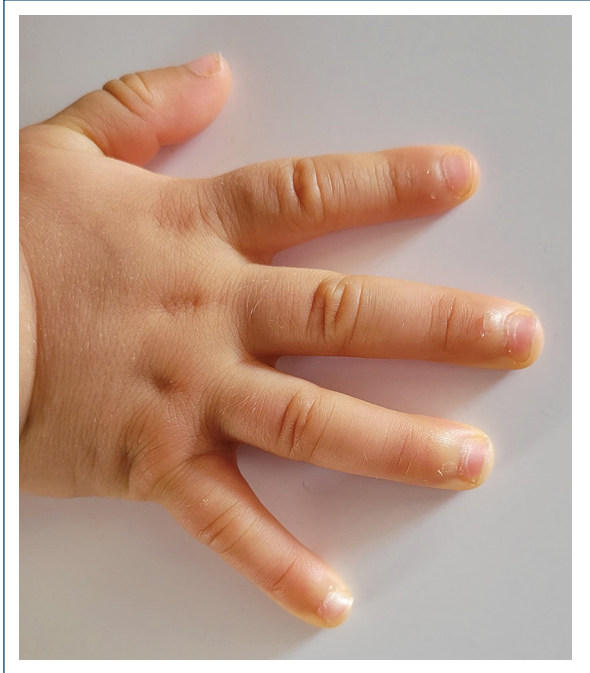


Figura 2. Complete resolution of hyperpigmentation at 12 months of age.

neurofibromatosis type 1^{1,2}. Recognition of this rare presentation in infants with lighter phototypes avoids unnecessary investigations and allows reassurance of parents regarding its benign and self-limited course.

Funding

None.

Conflicts of interest

None.

Ethical considerations

Protection of human subjects and animals. The authors declare that no experiments on humans or animals were performed for this research.

Confidentiality, informed consent, and ethical approval. The authors have followed their institution's confidentiality protocols, obtained informed consent from all patients, and secured approval from the Ethics Committee. SAGER guidelines have been followed as applicable to the nature of the study.

Declaration on the use of artificial intelligence (AI). The authors declare that no generative artificial intelligence was used in the writing or creation of the content of this manuscript.

References

1. Queirós C, Casinhas Santos M, Pimenta R, Tapadinhas C, Filipe P. Transient cutaneous alterations of the newborn. *EMJ*. 2021;6:97-106.
2. Wang L, Zuo D, Sun L. Transient neonatal hyperpigmentation of the proximal nail fold in a Chinese infant: a case report. *J Int Med Res*. 2022; 50(1):3000605211067748.
3. Kawai T, Hayashi R, Yokoyama R, Abe R. Case of transient neonatal hyperpigmentation of the proximal nail fold. *J Dermatol*. 2021;48:e528-9.
4. Vázquez-Osorio I, Pita Da Veiga G, Labandeira J, Vázquez-Veiga H. Hyperpigmentation of an Infant's fingers and toes. *Actas Dermosifiliogr*. 2020;111:875.