Portuguese Journal of Dermatology and Venereology

Permanyer

Check for updates

Port J Dermatol and Venereol.

CASE REPORT

Dermoscopy as a significant tool for diagnosing an exuberant case of human immunodeficiency virus-associated pityriasis lichenoides et varioliformis acuta

Dermatoscopia como ferramenta importante no diagnóstico de caso exuberante de pitiriase liquenoide e varioliforme aguda associado ao HIV

Rafaella C. Zanatta, Silvio C.F. Giovanni-Filho, Carolina F. Baldecerra, Thaís C. Silva-Bachio, Daiane de Souza, and Cássio R. Moreira*

Department of Dermatology, Municipal Health Authority of Apucarana, Paraná, Brazil

Abstract

Pityriasis lichenoides et varioliformis acuta (PLEVA) is a rare dermatological condition of uncertain etiology characterized by polymorphic and often exuberant skin lesions. The use of dermoscopy has been successfully applied for the early diagnosis of this pathology, as well as in distinguishing it from other potential differential diagnoses. In this study, we present the dermoscopic features observed in a severe case of human immunodeficiency virus-associated PLEVA, which are consistent with those previously described in the literature. Furthermore, we describe a dermoscopic pattern that has not yet been reported in the studies published to date. Dermoscopy is an excellent diagnostic tool that aids in the early detection and accurate characterization of skin lesions. Therefore, knowledge of the dermoscopic patterns of this disease is essential to improve early suspicion and diagnostic accuracy.

Keywords: Pityriasis lichenoides et varioliformis acuta. Human immunodeficiency virus. Dermoscopy.

Resumo

Pitiriase Liquenoide e Varioliforme Aguda (PLEVA) é uma afecção dermatológica rara, de etiologia ainda não completamente esclarecida, caracterizada pelo aparecimento de lesões cutâneas exuberantes nos indivíduos acometidos. A dermatoscopia tem se mostrado uma ferramenta valiosa no diagnóstico precoce dessa condição, além de contribuir para a sua diferenciação em relação a outras dermatoses de apresentação clínica semelhante. Neste relato, descrevemos as características dermatoscópicas observadas em um caso exuberante de PLEVA associado à infecção pelo HIV, as quais são compatíveis com aquelas previamente descritas na literatura. Além disso, relatamos um padrão dermatoscópico ainda não documentado em publicações anteriores. A dermatoscopia constitui um instrumento diagnóstico de grande utilidade, por permitir a identificação precoce e a caracterização detalhada das lesões cutâneas. Assim, o conhecimento dos padrões dermatoscópicos característicos da PLEVA é fundamental para aumentar o grau de suspeição clínica e favorecer o diagnóstico precoce dessa enfermidade.

Palavras-chave: PLEVA. HIV. Dermatoscopia.

***Correspondence:**
Rafaella C. Zanatta
E-mail: rafaella.cz@hotmail.com

Received: 05-11-2025
Accepted: 18-12-2025
DOI: 10.24875/PJDV.25000083

Available online: 29-01-2026
Port J Dermatol and Venereol. (ahead of print)
www.portuguesejournalofdermatology.com

2795-501X / © 2025 Portuguese Society of Dermatology and Venereology. Published by Permanyer. This is an open access article under the CC BY-NC-ND license (http://creativecommons.org/licenses/by-nc-nd/4.0/).

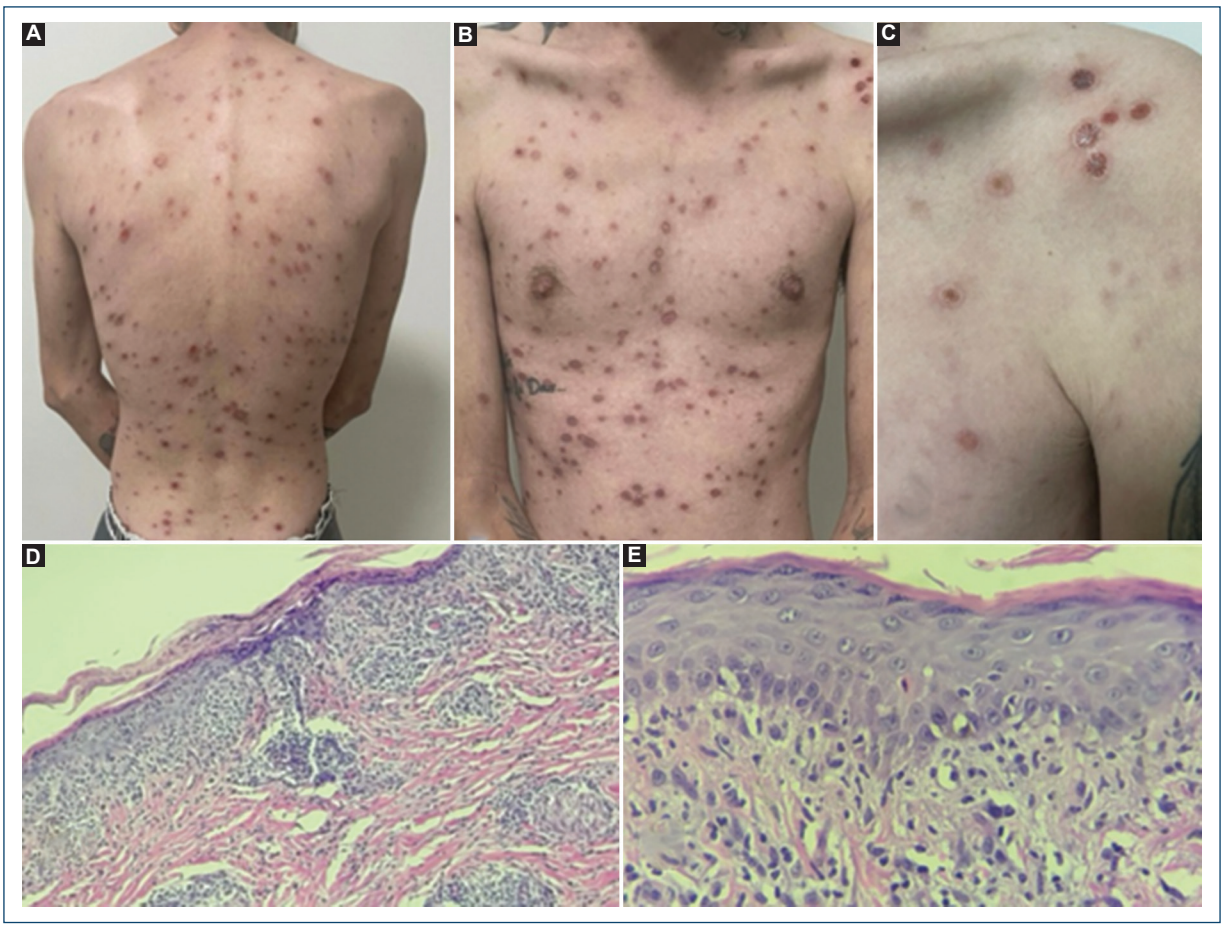

Figure 1: A-C: multiple erythematous-violaceous macules and papules, some with an ulceronecrotic surface, predominantly located on the upper limbs and trunk. Note the lesions in different stages of progression in C. **D** and **E:** histopathological findings showing a horizontal band infiltrate at the dermoepidermal junction, perivascular infiltration, parakeratosis, exocytosis of lymphocytes and neutrophils into the stratum corneum, forming corneal microabscesses.

Introduction

Pityriasis lichenoides et varioliformis acuta (PLEVA) is a rare dermatological condition of uncertain etiology, predominantly affecting young adults. Proposed triggers include medication use, vaccinations, and inflammatory responses to infectious agents, notably the human immunodeficiency virus (HIV)[1].

Clinically, PLEVA manifests as the sudden onset of multiple erythematous macules that progress into pustules or vesicles containing hemorrhagic fluid, often culminating in central ulcerations. Systemic symptoms can be present or absent alongside dermatological presentation[2,3]. Diagnosis relies on clinical assessment corroborated by histopathological findings[4]. However, histopathological examination may not be immediately available in all clinical settings, highlighting the importance of a noninvasive diagnostic tool. Dermoscopy is an invaluable tool in the early diagnosis of this condition, offering distinct features that aid in differential diagnosis[2,5]. We present a case of HIV-associated PLEVA, confirmed through histopathology, with an exuberant presentation of lesions displaying dermoscopic features consistent with the condition.

Case report

A 27-year-old male patient with a confirmed HIV diagnosis presented with a 3-week history of sudden onset erythematous macules evolving into papules and plaques with ulceronecrotic surfaces. The lesions predominantly affected the trunk and upper limbs (Fig. 1A-C).

Dermoscopy was performed using a polarized handheld dermatoscope at ×10 magnification and revealed

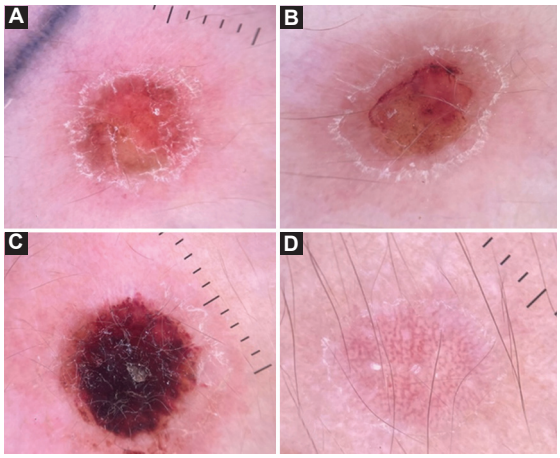

Figure 2: A and **B:** target-like pattern formed by a peripheral vascular outer ring followed by intermediate white scales and a center with a yellow-brownish mass. **C:** center formed by a hematinic crust, followed by a subtle peripheral white scale, surrounded by a slight erythematous halo. **D:** discreet erythematous vascular halo and thin circular white scale, encircling a vascular network composed of irregular linear vessels, occasionally forming vascular loops.

distinct morphological patterns. The most characteristic was target-like lesions composed of a peripheral vascular ring, intermediate white scales, and a red- brown central area (Fig. 2A and B). Additional findings included lesions with a central hematic crust, surrounded by white peripheral scaling and a faint erythematous halo (Fig. 2C). The third most observed pattern consisted of lesions with minimal or absent erythematous halos, fine circular white scaling, and a vascular network of irregular linear vessels occasionally forming vascular loops (Fig. 2D).

Histopathology confirmed the diagnosis of PLEVA, demonstrating a vacuolar interface dermatitis with features such as parakeratosis, lymphocytic and neutrophilic exocytosis, and the formation of corneal microabscesses (Fig. 1D and E).

Conclusion

Dermoscopy represents a valuable adjunctive diagnostic tool in cases of PLEVA, facilitating differentiation from clinically similar conditions such as viral exanthems, varicella, and guttate psoriasis[5]. The dermoscopic findings observed in our patient are largely consistent with those previously described in the literature, including the well-established target-like pattern considered pathognomonic by several authors. In addition, we describe a dermoscopic presentation not previously reported, characterized by a central vascular pattern composed of tortuous linear vessels. These observations reinforce the relevance of dermoscopy as a rapid, noninvasive bedside tool. Further studies are warranted to better characterize dermoscopic patterns of PLEVA and to support the development of standardized diagnostic criteria.

Funding

This research has not received any specific grant from agencies in the public, commercial, or for-profit sectors.

Conflicts of interest

The authors declare no conflicts of interest.

Ethical considerations

Protection of human subjects and animals. The authors declare that no experiments on humans or animals were performed for this research.

Confidentiality, informed consent, and ethical approval. The authors have followed their institution's confidentiality protocols, obtained informed consent from all patients, and secured approval from the Ethics Committee. SAGER guidelines have been followed as applicable to the nature of the study.

Declaration on the use of artificial intelligence. The authors declare that no generative artificial intelligence was used in the writing or creation of the content of this manuscript.

References

1. Relvas M, Santiago L, Cardoso JC, Oliveira H. Pityriasis lichenoides et varioliformis acuta as presenting feature of acute human immunodeficiency virus infection. BMJ Case Rep. 2019;12:e231864.
2. Arias-Rodriguez C, Hoyos-Gaviria JG, Muñoz-Monsalve AM, Hernandez-Martinez A. Dermoscopy of pityriasis lichenoides et varioliformis acuta (PLEVA). An Bras Dermatol. 2024;99:120-3.
3. Bellinato F, Maurelli M, Gisondi P, Girolomoni G. A systematic review of treatments for pityriasis lichenoides. J Eur Acad Dermatol Venereol. 2019;33:2039-49.
4. Clarey DD, Lauer SR, Trowbridge RM. Clinical, dermatoscopic, and histological findings in a diagnosis of pityriasis lichenoides. Cureus. 2020;12:e8725.
5. Ankad BS, Beergouder SL. Pityriasis lichenoides et varioliformis acuta in skin of color: new observations by dermoscopy. Dermatol Pract Concept. 2017;7:27-34.