

JAK inhibitors for atopic dermatitis with comorbid immune diseases: a therapeutic option?

Inibidores da JAK na dermatite atópica com doenças imunes concomitantes: uma opção terapêutica?

Mélissa Mendes-de Carvalho* and Margarida Moura Valejo-Coelho

Department of Dermatology and Venereology, Unidade Local de Lisboa Ocidental, Lisboa, Portugal

Abstract

Atopic dermatitis (AD) is a heterogeneous inflammatory disease involving multiple immune pathways, often coexisting with other systemic immune-mediated conditions. We report two cases of severe AD associated with Crohn's disease and axial spondyloarthritis, illustrating the therapeutic challenges and the relevance of multidisciplinary management. Both patients had inadequate or secondary loss of response to previous systemic therapies, including dupilumab. Following coordinated evaluation between Dermatology and Gastroenterology or Rheumatology, treatment with upadacitinib was initiated, leading to rapid and marked improvement in eczema severity, pruritus, and associated systemic symptoms. These cases highlight the importance of recognizing overlapping inflammatory mechanisms and the potential benefit of Janus kinase inhibition in patients with multisystem immune-mediated disease, offering broader cytokine modulation and simplified treatment regimens.

Keywords: Atopic dermatitis. Janus kinase inhibitors. Multidisciplinary management.

Resumo

A dermatite atópica é uma doença inflamatória heterogénea que envolve múltiplas vias imunitárias, frequentemente coexistindo com outras doenças sistémicas imunomediadas. Apresentamos dois casos de dermatite atópica grave associada a doença de Crohn e espondiloartrite axial, ilustrando os desafios terapêuticos e a relevância de uma abordagem multidisciplinar. Ambos os doentes apresentaram resposta inadequada ou perda secundária de eficácia a terapêuticas sistémicas prévias, incluindo dupilumab. Após avaliação coordenada entre a Dermatologia e a Gastrenterologia ou Reumatologia, foi iniciado tratamento com upadacitinib, conduzindo a uma melhoria rápida e marcada na gravidade do eczema, no prurido e nos sintomas sistémicos associados. Estes casos realçam a importância de reconhecer mecanismos inflamatórios sobrepostos e o potencial benefício da inibição da via JAK em doentes com doenças imunomediadas multissistémicas, oferecendo uma imunomodulação mais ampla e regimes terapêuticos simplificados.

Palavras chave: Dermatite atópica. Inibidores da JAK. Abordagem multidisciplinar.

*Correspondence:

Mélissa Mendes-de Carvalho

E-mail: mm.decarvalho@outlook.com

2795-501X / © 2025 Portuguese Society of Dermatology and Venereology. Published by Permanyer. This is an open access article under the CC BY-NC-ND license (<http://creativecommons.org/licenses/by-nc-nd/4.0/>).

Received: 27-11-2025

Accepted: 31-01-2025

DOI: 10.24875/PJDV.25000087

Available online: 17-03-2026

Port J Dermatol and Venereol. (ahead of print)

www.portuguesejournalofdermatology.com

Introduction

Atopic dermatitis (AD) is increasingly recognized as a heterogeneous and complex inflammatory disease, involving a multifaceted immune network with contributions from Th2, Th22, Th17, and even Th1 pathways, resulting in diverse clinical phenotypes and variable treatment responses^{1,2}. This heterogeneity presents therapeutic challenges, particularly in moderate-to-severe AD patients with concomitant systemic immune-mediated diseases that influence treatment selection and overall management strategy³. We present two clinical cases that exemplify the need for coordinated, multi-disciplinary care in severe AD with coexisting immune-mediated conditions and discuss the therapeutic role of Janus kinase (JAK) inhibitors in this context.

Clinical cases

Case 1

A 24-year-old male with long-standing AD and Crohn's disease was evaluated in a Dermatology consultation due to uncontrolled eczema. Previous dermatological treatments included systemic corticosteroids, cyclosporine, and later dupilumab, which provided initial improvement but resulted in secondary loss of efficacy after 5 months. The patient was concurrently under infliximab for Crohn's disease, initially effective but requiring dose-interval reduction from 9 to 6 weeks due to increased bowel movements. On dermatologic assessment, he presented with severe disease activity (EASI 27.1; pruritus NRS 9/10) (Fig. 1). After multidisciplinary discussion between Dermatology and Gastroenterology, infliximab was stopped, and upadacitinib 45 mg/day was initiated and subsequently tapered to 30 mg/day after 1 month. At 3 months, he showed marked clinical improvement (EASI 2.6; NRS 1/10) (Fig. 2) and concurrent optimization of gastrointestinal symptoms. Importantly, clinical control was achieved with a simplified regimen comprising a single daily oral agent.

Case 2

A 32-year-old male with a 10-year history of AD and associated chronic prurigo reported intense pruritus and widespread eczematous lesions (EASI 17.3) (Fig. 3). He also described chronic mixed-pattern low back pain suggestive of axial spondyloarthritis. Previous

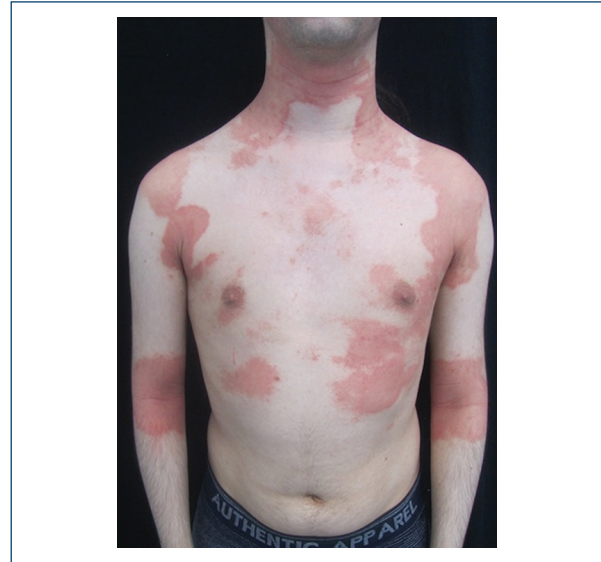

Figure 1. Monomorphic dermatosis localized to the neck, trunk, and upper limbs, characterized by well-demarcated erythematous patches and scaly surface.

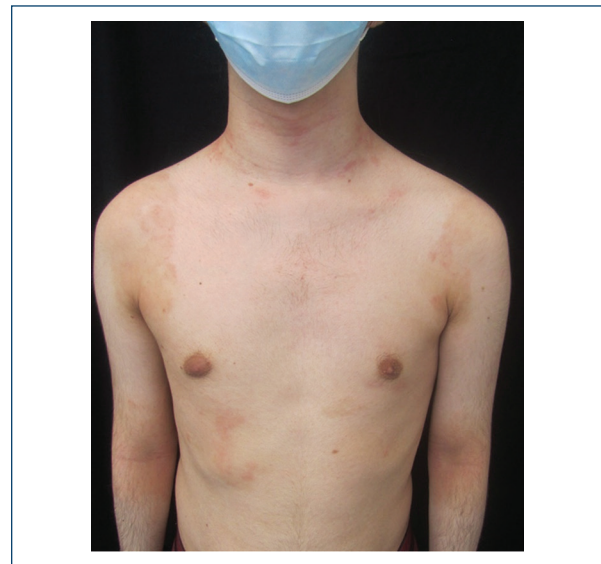


Figure 2. Near-complete resolution of the dermatosis at 3-month follow-up, with only a few residual erythematous papules and post-inflammatory hyperpigmentation.

treatments included systemic corticosteroid cycles, topical corticosteroids, antihistamines, a short course of cyclosporine, and 4 months of dupilumab with gradual loss of efficacy. Rheumatological evaluation confirmed findings consistent with axial spondyloarthritis, unresponsive to non-steroidal anti-inflammatory drugs and

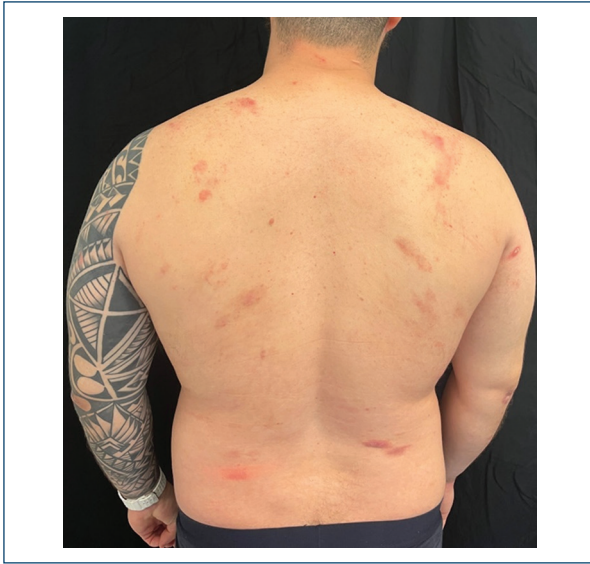

Figure 3. Dermatitis on the posterior trunk characterized by erythematous papules and plaques with a slightly scaly surface and erythematous-brownish nodular areas.

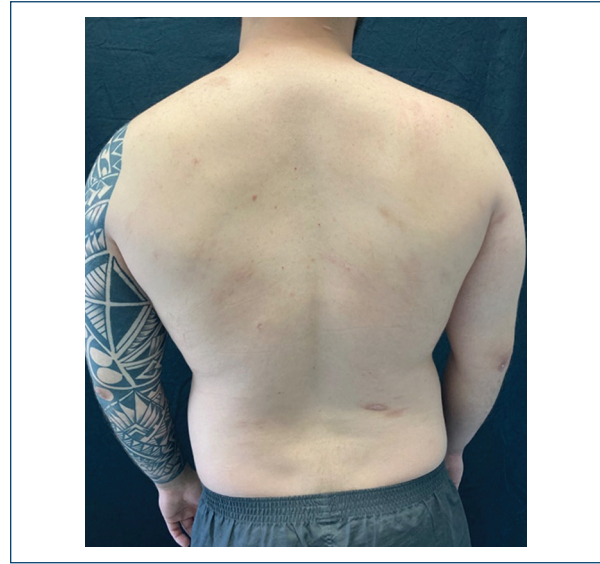


Figure 4. Marked improvement after 2 weeks of treatment, with only post-inflammatory hyperpigmented scarring lesions.

physical therapy, and anti-tumor necrosis factor therapy was being considered. A multidisciplinary discussion led to initiation of upadacitinib 15 mg/day, the recommended dose for axial spondyloarthritis and an approved dose for AD, following a lowest-effective-dose approach. After 2 weeks, the patient reported striking improvement in pruritus and mild-to-moderate improvement in eczema (EASI 6.2), with complete resolution of prurigo nodules (Fig. 4). The rapid dermatological response, together with potential benefit on musculo-skeletal symptoms, reinforced the value of targeting shared inflammatory pathways.

In both cases, recommended baseline screening for latent infections (human immunodeficiency virus, hepatitis B and C, and tuberculosis) was performed before upadacitinib initiation and yielded negative results. No adverse events have been reported to date.

Discussion

These two cases illustrate the complex clinical scenarios often faced in the management of severe AD, particularly when accompanied by systemic immune-mediated diseases. The molecular and clinical heterogeneity of AD implies that treatment strategies must extend beyond a Th2-centric model^{1,2}. In this context, targeting upstream or intracellular signaling pathways, such as the JAK-STAT axis, may provide

broader and more durable inflammatory control^{1,3}. Upadacitinib predominantly inhibits JAK1, modulating JAK-STAT signaling downstream of multiple cytokines. This enables partial and reversible inhibition of several inflammatory pathways, including those mediated by interleukin (IL)-4, IL-13, IL-31, thymic stromal lymphopoietin, IL-22, and interferon- γ . By simultaneously targeting multiple cytokine pathways, JAK inhibitors may offer particular advantages in patients with overlapping immune-mediated diseases, in contrast to biologic therapies that selectively block single cytokines³⁻⁵.

In both cases, upadacitinib provided rapid and significant improvement in cutaneous symptoms, while also benefiting comorbid systemic inflammatory disease. Importantly, the dose selection differed according to the predominant comorbid condition and approved therapeutic indications. In case 1, upadacitinib was initiated at the recommended induction dose for Crohn's disease (45 mg/day). In contrast, in case 2, a multidisciplinary discussion supported initiation of upadacitinib 15 mg/day, corresponding to the recommended dose for axial spondyloarthritis and an approved dose for AD. Equally important is the collaborative decision-making between Dermatology and other specialties. This multidisciplinary approach enabled the selection of a single oral therapy addressing multiple inflammatory pathways, simplifying treatment regimens and optimizing global clinical outcomes. These cases highlight the

need to recognize shared immunological mechanisms across diseases and adopt therapeutic strategies reflecting the full spectrum of inflammatory involvement.

Funding

None.

Conflicts of interest

None.

Ethical considerations

Protection of human subjects and animals. The authors declare that no experiments on humans or animals were performed for this research.

Confidentiality, informed consent, and ethical approval. The authors have followed their institution's confidentiality protocols, obtained informed consent

from all patients, and secured approval from the Ethics Committee. SAGER guidelines have been followed as applicable to the nature of the study.

Declaration on the use of artificial intelligence (AI). The authors declare that no generative artificial intelligence was used in the writing or creation of the content of this manuscript.

References

1. Huang IH, Chung WH, Wu PC, Chen CB. JAK-STAT signaling pathway in the pathogenesis of atopic dermatitis: an updated review. *Front Immunol.* 2022;13:1068260.
2. Tsiogka A, Kyriazopoulou M, Kontochristopoulos G, Nicolaidou E, Stratis A, Rigopoulos D, et al. The JAK/STAT pathway and its selective inhibition in the treatment of atopic dermatitis: a systematic review. *J Clin Med.* 2022;11:4431.
3. He Q, Xie X, Chen Q, Li W, Song Z, Wang X, et al. Janus kinase inhibitors in atopic dermatitis: an umbrella review of meta-analyses. *Front Immunol.* 2024;15:1342810.
4. Burmester GR, Deodhar A, Irvine AD, Panaccione R, Winthrop KL, Vleugels RA, et al. Safety profile of upadacitinib: descriptive analysis in over 27,000 patient-years across rheumatoid arthritis, psoriatic arthritis, axial spondyloarthritis, atopic dermatitis, and inflammatory bowel disease. *Adv Ther.* 2025;42:5215-37.
5. Kim Y, Seo G, Koopman JJ, Yee J. Real-world effectiveness and safety of JAK inhibitors in atopic dermatitis: a systematic review and meta-analysis. *Clin Exp Allergy.* 2025;55:755-72.