

Onycholysis associated with acute bacterial tonsillitis: case report

Onicólise associada a amigdalite bacteriana aguda: relato de caso

Marcelo Pacheco-Silva*^{ORCID}, Joana Reis^{ORCID}, Katarina Kiesel-Rodrigues^{ORCID}, and João Alves^{ORCID}

Unidade Local de Saúde Almada-Seixal, Centro de Responsabilidade Integrada de Dermatovenereologia, Almada, Portugal

Abstract

Onycholysis is a common nail disorder with multiple causes. Transverse onycholysis bordered by a proximal erythematous rim is a typical manifestation of nail psoriasis. Its isolated onset after bacterial tonsillitis is uncommon and may pose a diagnostic challenge. We describe a previously healthy 20-year-old female who developed transverse onycholysis 2 weeks after treatment with amoxicillin/clavulanic acid for acute bacterial tonsillitis. Clinical examination revealed characteristic psoriatic nail changes, including a proximal erythematous-orange border and mild subungual hyperkeratosis. A diagnosis of post-streptococcal nail psoriasis was considered. She was treated with topical betamethasone/calcipotriol and advised on protective nail care, achieving marked improvement after 3 months. This case reinforces the association between streptococcal infections and psoriatic manifestations and highlights the diagnostic value of recognizing specific patterns of onycholysis. Early identification of psoriatic nail disease can prevent unnecessary investigations and enable timely, appropriate management.

Keywords: Onycholysis. Nail psoriasis. Streptococcal infection. Tonsillitis. Case report.

Resumo

A onicólise é uma alteração ungueal frequente com múltiplas causas possíveis. A onicólise transversal com bordo eritematoso proximal é uma manifestação típica de psoríase ungueal. O seu aparecimento isolado após amigdalite bacteriana é incomum e pode dificultar o diagnóstico. Descrevemos o caso de uma mulher de 20 anos, saudável, que desenvolveu onicólise transversal duas semanas após tratamento com amoxicilina/ácido clavulânico por amigdalite bacteriana aguda. O exame objetivo revelou alterações ungueais características de psoríase, como bordo eritemato-alaranjado proximal e discreta hiperqueratose subungueal. Foi considerado o diagnóstico de psoríase ungueal pós-estreptocócica. Foi tratada com betametasona/calcipotriol tópico e medidas gerais de proteção ungueal, com melhoria marcada ao fim de três meses. Este caso reforça a associação entre infeções estreptocócicas e manifestações psoriáticas, salientando o valor diagnóstico do reconhecimento de padrões específicos de onicólise. A identificação precoce permite evitar exames desnecessários e otimizar o tratamento.

Palavras-chave: Onicólise. Psoríase ungueal. Infeção estreptocócica. Amigdalite. Caso clínico.

*Correspondence:

Marcelo Pacheco-Silva

E-mail: marcelocpsilva@gmail.com

2795-501X / © 2026 Portuguese Society of Dermatology and Venereology. Published by Permanyer. This is an open access article under the CC BY-NC-ND license (<http://creativecommons.org/licenses/by-nc-nd/4.0/>).

Received: 05-12-2025

Accepted: 18-04-2026

DOI: 10.24875/PJDV.25000091

Available online: 12-05-2026

Port J Dermatol and Venereol. (ahead of print)

www.portuguesejournalofdermatology.com

Introduction

Onycholysis, defined as the separation of the nail plate from the underlying and/or lateral supporting structures, may occur in a wide range of dermatological diseases and infectious, traumatic, or systemic conditions. The clinical pattern can provide important diagnostic clues. Transverse onycholysis bordered proximally by an erythematous band is a well-recognized manifestation of nail psoriasis.¹ Nail involvement occurs in up to 50% of patients with psoriasis. It may represent the sole manifestation of psoriasis in up to 5% of patients, a recognized but often underdiagnosed presentation due to the absence of cutaneous findings.^{2,3} Streptococcal infection is a well-established trigger for guttate psoriasis and exacerbations of chronic plaque psoriasis, particularly in genetically predisposed individuals such as carriers of the HLA-Cw6 allele.⁴ However, reports of isolated nail psoriasis triggered by streptococcal infection, without cutaneous lesions, remain exceptionally rare.

We report a case of transverse onycholysis following acute bacterial tonsillitis, underscoring the role of infection as a trigger of psoriatic nail disease and the importance of recognizing typical nail changes.

Case report

A 20-year-old female, with no personal or family history of dermatological disease, presented with nail changes that had progressively developed over 2 months. She denied any precipitating trauma, manicure-related injury, or exposure to irritants. Two weeks before the onset of nail symptoms, she had been treated with amoxicillin/clavulanic acid for clinically diagnosed acute bacterial tonsillitis, without microbiological confirmation of *Streptococcus*. The patient reported low-grade fever, and the symptoms lasted approximately 1 week. Physical examination revealed transverse onycholysis affecting approximately one-quarter to one-third of the nail plate in several fingernails. A proximal erythematous-orange border clearly demarcated the onycholytic area, and mild subungual hyperkeratosis was present (Fig. 1). No toenail involvement was observed. Examination of the remaining skin, scalp, mucosal, and osteoarticular examination showed no abnormalities.

Based on the characteristic pattern and the recent history of streptococcal infection, post-streptococcal nail psoriasis was considered the most likely diagnosis.

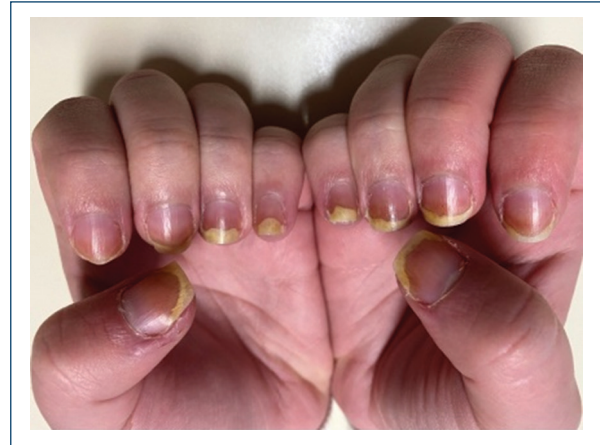


Figure 1. Transverse onycholysis of a quarter to a third of the nail plate in several fingernails, with an erythematous-orange line surrounding the proximal area of onycholysis, and mild subungual hyperkeratosis.

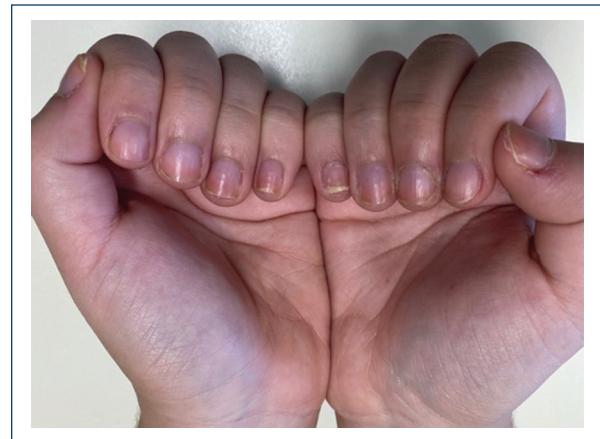

Figure 2. Substantial improvement in nail changes 3 months after treatment.

Topical therapy with betamethasone/calcipotriol foam was initiated, together with general protective nail care recommendations: keeping nails short, avoiding repetitive trauma, and minimizing prolonged exposure to water.

At follow-up 3 months later, she showed significant clinical improvement with reduced onycholysis and nearly complete resolution of subungual hyperkeratosis (Fig. 2). No adverse effects were observed.

Discussion

Onycholysis presents with different patterns depending on the underlying cause. When most nails show

transverse linear onycholysis, a systemic etiology should be considered. Importantly, transverse onycholysis with a proximal erythematous border is a characteristic pattern of nail psoriasis.¹

This case highlights a characteristic presentation of nail psoriasis temporally associated with bacterial tonsillitis, supporting the role of streptococcal infection as a trigger for psoriatic disease. Nail psoriasis frequently involves the nail bed, causing transverse onycholysis, subungual hyperkeratosis, splinter hemorrhages, and the “oil drop” sign.^{2,5} The proximal erythematous border seen in this case is considered a distinguishing feature of psoriatic onycholysis, suggestive of active inflammation at the onychodermal band.¹ This helps differentiate it from traumatic onycholysis, in which the proximal border is typically pale or normal.

Although most cases of nail psoriasis occur in the context of cutaneous psoriasis or psoriatic arthritis, nail-only disease remains challenging to diagnose.³ Clinical evaluation and dermoscopy are usually sufficient. At the same time, a biopsy is reserved for cases where the diagnosis remains uncertain.²

Therapy depends on severity and impact on quality of life. In addition to the psychological impact that the appearance of nail changes implies, nail psoriasis is related to more severe forms of psoriasis and an increased risk of psoriatic arthritis,² resulting in functional impact and decreased quality of life.^{2,3} Its management must integrate the approach to patients with psoriasis. High-potency topical corticosteroids, with or without Vitamin D analogs, are recommended as first-line treatment for isolated nail psoriasis.⁵ In more severe or refractory disease, intralesional corticosteroids or systemic therapies such as methotrexate, acitretin, or biologics may be considered.^{3,5} General nail care should be advised; nails must be kept short and trauma avoided.³

A limitation of this report is the absence of microbiological confirmation of streptococcal infection and the lack of genetic testing (e.g., HLA-Cw6), which could further support the proposed association.

Conclusion

Although isolated nail psoriasis is uncommon, its recognition is clinically relevant, particularly in patients without cutaneous disease, where misdiagnosis may lead to unnecessary investigations or inappropriate management. This case reinforces the importance of recognizing typical patterns of onycholysis and considering psoriasis in the differential diagnosis, particularly following streptococcal infection.

Funding

None.

Conflicts of interest

None.

Ethical considerations

Protection of humans and animals. The authors declare that no experiments involving humans or animals were conducted for this research.

Confidentiality, informed consent, and ethical approval. The authors have followed their institution’s confidentiality protocols, obtained informed consent from patients, and received approval from the Ethics Committee. The SAGER guidelines were followed according to the nature of the study.

Declaration on the use of artificial intelligence. The authors declare that no generative artificial intelligence was used in the writing of this manuscript.

References

1. Navarro L. Pattern diagnosis of onycholysis. *J EADV Clin Pract.* 2023;2:213-24.
2. Haneke E. Nail psoriasis: clinical features, pathogenesis, differential diagnoses, and management. *Psoriasis (Auckl).* 2017;7:51-63.
3. Canal-García E, Bosch-Amate X, Belinchón I, Puig L. Nail psoriasis. *Actas Dermosifiliogr.* 2022;113:481-90.
4. Zhou S, Yao Z. Roles of infection in psoriasis. *Int J Mol Sci.* 2022;23:6955.
5. Crowley JJ, Weinberg JM, Wu JJ, Robertson AD, Van Voorhees AS, National Psoriasis Foundation. Treatment of nail psoriasis: best practice recommendations from the medical board of the national psoriasis foundation. *JAMA Dermatol.* 2015;151:87-94.