





# Complication following treatment with a microneedling technique for a female pattern hair loss: hair dye-induced tattoo-like pigmentation

*Complicação pós microagulhamento em alopecia de padrão feminino: pigmentação semelhante a tatuagem induzida por tintura de cabelo*

Anne K. Leroy , Flavia Oliveira-Xavier-de Brito , Rita F. Cortez-de Almeida ,  
Daniel Fernandes-Melo 

Department of Dermatology, Advanced Institute of Trichology–Rio de Janeiro, Rio de Janeiro, Brazil

## Abstract

Microinfusion of drugs into the skin (MMP<sup>®</sup>) is a Brazilian microneedling technique that employs professional tattoo devices for the delivery of pharmacological agents in conditions such as female pattern hair loss. We report an unexpected complication in a 44-year-old female patient who underwent hair dyeing 2 days after the procedure and subsequently developed linear pigmentation on the scalp resembling a tattoo. Trichoscopy revealed pigment deposition at the needle entry points, likely resulting from penetration of the hair dye. Although adverse effects of MMP<sup>®</sup> are generally mild, this case highlights the importance of counseling patients regarding the use of hair dye following the procedure.

**Keywords:** Androgenetic alopecia. Microinfusion of drugs into the skin<sup>®</sup>. Female pattern hair loss.

## Resumo

MMP<sup>®</sup> (microinfusão de medicamentos na pele) é uma técnica brasileira de microagulhamento que utiliza equipamentos de tatuagem profissional para administração de fármacos em condições como a Alopecia de padrão feminino (FPHL). Relatamos complicação inesperada em paciente feminina de 44 anos que realizou tintura capilar dois dias após o procedimento, evoluindo com pigmentação linear semelhante a tatuagem no couro cabeludo. A tricoscopia evidenciou depósito pigmentário nos pontos de entrada das agulhas, provavelmente decorrente da penetração da tintura. Embora os efeitos adversos do MMP<sup>®</sup> sejam, em geral, leves, este caso reforça a necessidade de orientar pacientes quanto ao uso da tintura pós-procedimento.

**Palavras-chave:** Alopecia androgenética, MMP<sup>®</sup>. Alopecia de padrão feminino.

### \*Correspondence:

Anne K. Leroy  
E-mail: [annekelly\\_l@hotmail.com](mailto:annekelly_l@hotmail.com)  
2795-501X / © 2026 Portuguese Society of Dermatology and Venereology. Published by Permayer. This is an open access article under the CC BY-NC-ND license (<http://creativecommons.org/licenses/by-nc-nd/4.0/>).

Received: 06-12-2025

Accepted: 14-01-2026

DOI: 10.24875/PJDV.25000092

Available online: 02-03-2026

Port J Dermatol and Venereol. (ahead of print)

[www.portuguesejournalofdermatology.com](http://www.portuguesejournalofdermatology.com)

## Introduction

MMP<sup>®</sup>, an acronym for microinfusion of drugs into the skin, is an innovative technique developed in Brazil that consists of microneedling performed with professional tattoo devices for the transdermal delivery of pharmacological agents<sup>1</sup>. It has been applied as an adjuvant treatment for androgenetic alopecia, particularly in cases of female pattern hair loss<sup>2,3</sup>. The method enables uniform infusion of substances into the dermis at an average depth of 1.0 to 1.5 mm, adjusted according to the clinical condition<sup>1</sup>. The procedure is generally well tolerated, with no reports of severe adverse events<sup>3</sup>.

This article describes the case of a patient who developed an unexpected complication following MMP<sup>®</sup> on the scalp, addressing its clinical, trichoscopic, and therapeutic aspects.

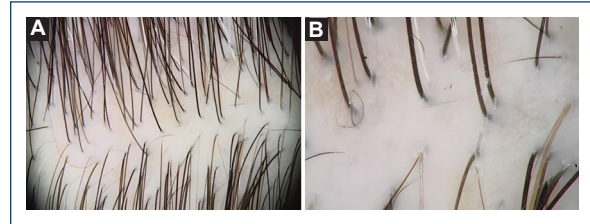## Clinical case

A 44-year-old female patient underwent a session of MMP<sup>®</sup> on her scalp, utilizing minoxidil and dutasteride to treat FPHL (Fig. 1). Two days post-procedure, she dyed her hair and unexpectedly observed several linear scalp pigmentations, which caused her significant distress. In the following days, trichoscopic examination revealed pigmentation at the entry points of the microneedles from the MMP<sup>®</sup> procedure, resembling a tattoo, likely due to hair dye impregnation (Fig. 2). To address this issue, a daily regimen of exfoliating shampoo and a topical solution containing corticosteroids and salicylic acid was recommended. Fortunately, after 7 days, the patient achieved complete resolution of the scalp pigmentation.

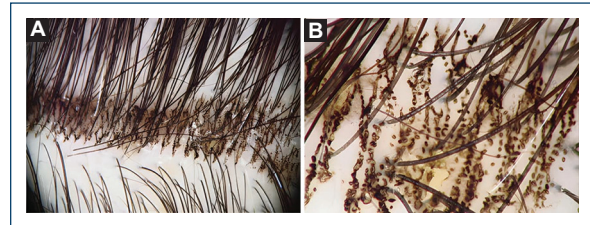
## Discussion

The MMP<sup>®</sup> procedure is performed using the Cheyenne tattoo machine along with sterile 27-Magnum needle cartridges to infuse medication into the skin<sup>2</sup>. The entry holes created by the 27-needle cartridge range from 6 to 10 microns in diameter, significantly smaller than the 0.3 mm diameter of a traditional needle shaft<sup>1,2</sup>.

While previous reports have suggested that MMP<sup>®</sup> openings close within approximately 4 h, thereby limiting further drug permeation, our case challenges this notion<sup>4</sup>. The patient experienced temporary tattoo-like linear pigmentations resulting from topical particles applied 2 days after the MMP<sup>®</sup> procedure.



**Figure 1.** Trichoscopy before the MMP<sup>®</sup> procedure. Magnification: **A:** ×20 and **B:** ×70.



**Figure 2.** Trichoscopy after MMP<sup>®</sup> procedure. Images reveal the pigmentation at the entry points of the micro-needles. Magnification: **A:** ×20 and **B:** ×70.

Overall, MMP<sup>®</sup> is associated with mild side effects, such as temporary pain and erythema at the application site, with no serious adverse events reported<sup>3</sup>. In this article, we present an additional side effect of MMP<sup>®</sup> that has not been previously described; nevertheless, it remains a safe treatment option.

This report underscores a potential post-procedure complication that can lead to both psychological and cosmetic concerns. It raises important questions regarding the optimal timing for recommending the use of hair dye, makeup, and hair fibers after MMP<sup>®</sup>, emphasizing the need to advise patients to observe a longer waiting period than previously believed before applying hair dye. Dermatologists must remain vigilant about this complication, particularly as MMP<sup>®</sup> gains popularity in treating common conditions like FPHL.

MMP<sup>®</sup> remains a safe option for the adjuvant treatment of Androgenetic Alopecia. Despite the report of another unexpected adverse event, its side effects are few, temporary, and not severe.

This article emphasizes the need for dermatologists to advise patients on delaying the use of hair dye and similar products after MMP<sup>®</sup> treatment to prevent cosmetic concerns. This report calls for increased awareness of potential complications as MMP<sup>®</sup> becomes more widely adopted for treating FPHL.

## Funding

None.

## Conflicts of interest

None.

## Ethical considerations

**Protection of human subjects and animals.** The authors declare that no experiments on humans or animals were performed for this research.

**Confidentiality, informed consent, and ethical approval.** The authors have followed their institution's confidentiality protocols, obtained informed consent from all patients, and secured approval from the Ethics

Committee. SAGER guidelines have been followed as applicable to the nature of the study.

**Declaration on the use of artificial intelligence (AI).** The authors declare that no generative artificial intelligence was used in the writing or creation of the content of this manuscript.

## References

1. Arbache S, Mattos ED, Diniz MF, Paiva PY, Roth D, Arbache ST, et al. How much medication is delivered in a novel drug delivery technique that uses a tattoo machine? *Int J Dermatol.* 2019;58:750-5.
2. Cortez De Almeida RF, Melo DF, Tosti A. Scalp microinfusion: a novel drug delivery technique for hair loss treatment. *Skin Appendage Disord.* 2023;9:81-3.
3. Gowda A, Healey B, Ezaldeen H, Merati M. A systematic review examining the potential adverse effects of microneedling. *J Clin Aesthet Dermatol.* 2021;1;14:45-54.
4. Duncan DI. Microneedling with biologicals: advantages and limitations. *Facial Plast Surg Clin North Am.* 2018;26:447-54.