Portuguese Journal of Dermatology and Venereology

Permanyer

Check for updates

Port J Dermatol and Venereol.

CASE REPORT

Rare coexistence of urticaria pigmentosa and HIV infection: a case report

Coexistência rara entre urticária pigmentosa e infecção pelo vírus da imunodeficiência humana: relato de caso

Thalyssa Figueiredo-Magalhães[1], Rebeca de Oliveira-Alves-Melo-Martins[1], Daniela Vale-Dias[1], Lizandra Cunha-de Carvalho[2], Bruna R. Santana-Vollrath[3], Thiago Vilas-Boas[1], and Luciana Mendes-dos Santos[1]*

[1]Department of Dermatology, Hospital Universitário Getúlio Vargas; [2]Department of Dermatology, Fundação de Medicina Tropical Doutor Heitor Vieira Dourado; [3]School of Medicine, Universidade do Estado do Amazonas. Manaus, Amazonas, Brazil

Abstract

Urticaria pigmentosa is the most common form of cutaneous mastocytosis. Its occurrence in people living with human immunodeficiency virus (HIV) is extremely uncommon, and the relationship between both conditions remains uncertain. We report the case of a 37-year-old male living with HIV on regular antiretroviral therapy, with an undetectable viral load and a preserved cluster of differentiation 4 count, who developed progressive erythematous-to-brown macules and papules on the trunk approximately 2 years after HIV diagnosis. Histopathological examination confirmed cutaneous mastocytosis. Although a causal association cannot be established, this rare coexistence adds to the limited literature and reinforces the importance of recognizing mastocytosis in adults living with HIV.

Keywords: Urticaria pigmentosa. Cutaneous mastocytosis. Mast cells. Human immunodeficiency virus. Case report.

Resumo

A urticária pigmentosa é a forma mais comum de mastocitose cutânea. Sua ocorrência em pessoas vivendo com HIV é extremamente incomum, e a relação entre ambas as condições permanece incerta. Relatamos o caso de um homem de 37 anos, vivendo com HIV, em uso regular de terapia antirretroviral, com carga viral indetectável e contagem preservada de linfócitos T CD4, que desenvolveu máculas e pápulas eritematoacastanhadas progressivas no tronco aproximadamente dois anos após o diagnóstico da infecção pelo HIV. O exame histopatológico confirmou mastocitose cutânea. Embora não seja possível estabelecer uma associação causal, essa rara coexistência amplia a limitada literatura sobre o tema e reforça a importância do reconhecimento da mastocitose em adultos vivendo com HIV.

Palavras-chave: Urticária pigmentosa. Mastocitose cutânea. Mastócitos. Vírus da imunodeficiência humana. Relato de caso.

***Correspondence:**
Thalyssa Figueiredo-Magalhães
E-mail: thalyssafigueiredo@gmail.com

Received: 15-07-2026
Accepted: 06-08-2026
DOI: 10.24875/PJDV.26000087

Available online: **16-11-2026**
Port J Dermatol and Venereol. **(ahead of print)**
www.portuguesejournalofdermatology.com

2795-501X / © 2025 Portuguese Society of Dermatology and Venereology. Published by Permanyer. This is an open access article under the CC BY-NC-ND license (http://creativecommons.org/licenses/by-nc-nd/4.0/).

Introduction

Mastocytosis comprises a spectrum of mast cell proliferative disorders, ranging from skin-confined disease to aggressive systemic forms that may be associated with myelodysplastic disorders. Urticaria pigmentosa (UP) is the most common form of cutaneous mastocytosis and is typically a benign and self-limited condition that predominantly affects children.[1,2]

Advances in the understanding of mastocytosis pathophysiology over the past decades have established the disease, in most cases, as a clonal hematopoietic disorder associated with somatic mutations in the *KIT* gene and an aberrant mast cell immunophenotype.[3]

Only a few cases of mastocytosis in people living with human immunodeficiency virus (HIV) have been reported in the literature, raising the question of whether this coexistence represents a coincidental finding or a possible immunological association. We report the uncommon case of an adult living with HIV who developed UP shortly after diagnosis.

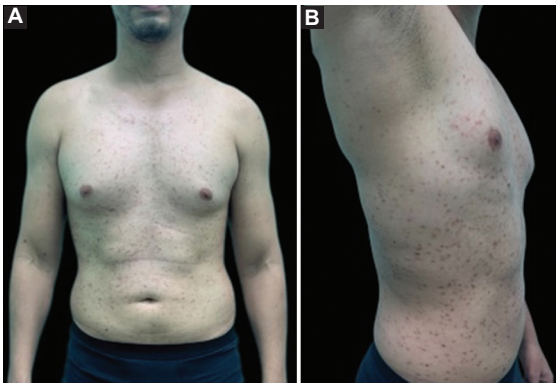

Figure 1. A: erythematous-to-brown macules and papules distributed over the anterior trunk and proximal regions of the upper and lower limbs. **B:** higher-magnification view of the cutaneous lesions.



Figure 2. Positive Darier sign induced by rubbing the lesion.

Case report

A 37-year-old male patient with a 10-year history of HIV infection, currently on regular antiretroviral therapy since 2016, presented with an undetectable viral load and a cluster of differentiation (CD4)+ T-cell count of 985 cells/mm^3. He reported the gradual onset of hyperpigmented macules over the past 8 years, initially arising along the midaxillary line and subsequently spreading to the trunk, abdomen, back, and proximal thighs. The eruption began approximately 2 years after HIV diagnosis. He denied associated pruritus or systemic symptoms.

Dermatological examination revealed multiple erythematous-to-brown macules and papules distributed across the anterior trunk and proximal portions of the upper and lower extremities (Fig. 1). Gentle rubbing of a representative lesion elicited a localized urticarial wheal, consistent with a positive Darier sign (Fig. 2).

Histopathological evaluation of lesional skin, using hematoxylin and eosin and toluidine blue staining, demonstrated a dermal inflammatory infiltrate composed predominantly of mast cells, accompanied by eosinophils and lymphocytes, findings consistent with cutaneous mastocytosis (Figs. 3 and 4). Systemic workup, including laboratory tests and abdominal ultrasonography, revealed no evidence of extracutaneous involvement. Serum tryptase level was 13.0 ng/mL, within the range more commonly observed in cutaneous-restricted disease.

The patient remains under regular outpatient follow-up, with no clinical or laboratory evidence of systemic progression to date. Symptomatic treatment with a second-generation H1-antihistamine was initiated. Phototherapy was recommended as adjunctive therapy; however, it has not yet been undertaken because it is not available through the public healthcare system.

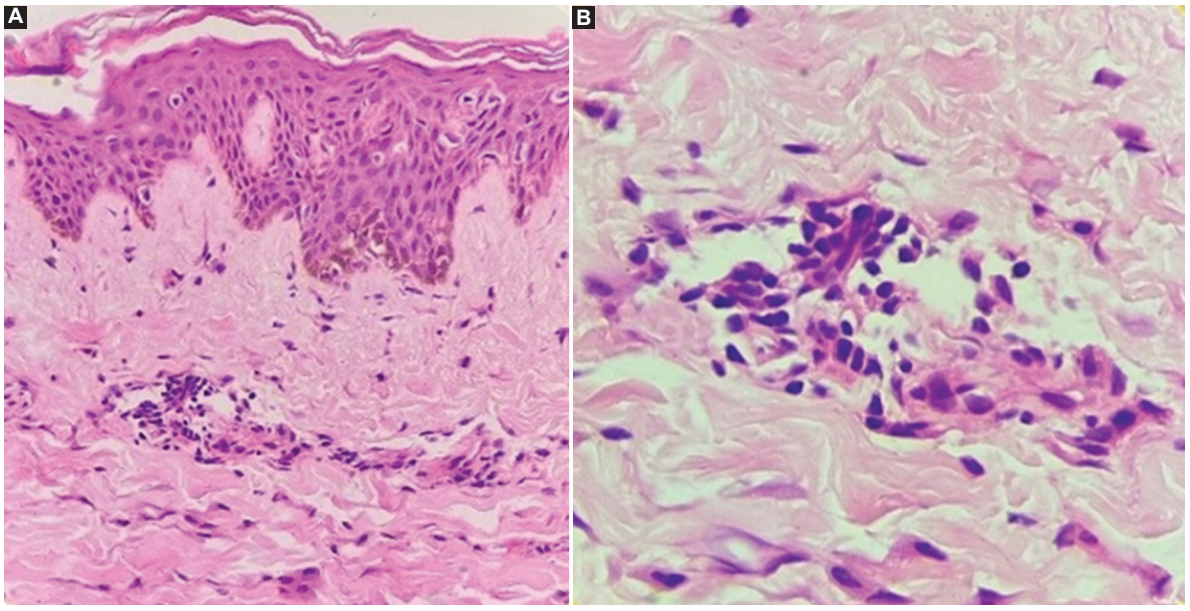

Figure 3. Histopathological features of cutaneous mastocytosis on hematoxylin and eosin staining. **A:** dermal inflammatory infiltrate composed predominantly of mast cells, associated with eosinophils, granulocytes, and scattered lymphocytes. **B:** higher-magnification view demonstrating aggregates of mast cells within the dermis.

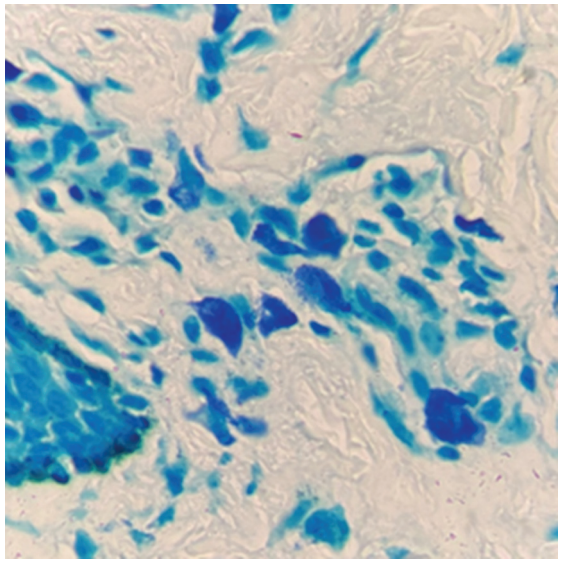

Figure 4. Special stain with toluidine blue demonstrating a dermal mast cell infiltrate.

Discussion

UP is the most common clinical presentation of cutaneous mastocytosis, especially in children, in whom lesions are typically polymorphic and often resolve spontaneously by adolescence. In contrast, adult-onset cutaneous mastocytosis is characterized by monomorphic lesions, frequent systemic involvement, and a chronic course. In people living with HIV, the clinical presentation appears to be similar to that observed in the general population, consisting of erythematous-to-brown macules or papules accompanied by a positive Darier's sign. This finding reflects the release of mast cell mediators following mechanical stimulation and was also observed in the present case.[1,4-6]

Although usually confined to the skin, mastocytosis is a clonal hematopoietic disorder, and serum tryptase levels and the extent of cutaneous involvement may reflect mast cell burden and disease severity. Systemic mastocytosis may present with a broad spectrum of manifestations, including gastrointestinal disturbances, neuropsychiatric complaints, musculoskeletal pain, and cardiac symptoms.[6]

The interaction between HIV and mast cells remains incompletely understood. Mast cells express several surface molecules involved in HIV entry, including CD4, CCR3, CCR5, and CXCR4, whereas viral proteins such as Tat and gp41 exhibit chemotactic properties that may promote mast cell recruitment and exposure to viral particles. Although HIV infection in basophils has been demonstrated, whether mast cells are similarly susceptible remains unclear. Increasing evidence suggests that mast cells may act as inducible reservoirs of latent HIV,

contributing to viral persistence through interactions with CD4+ T cells; however, the clinical relevance of this mechanism has yet to be established.[5,7-9]

Diagnosis is based on clinical findings and confirmed histopathologically by dermal mast cell infiltrates identified with toluidine blue or Giemsa staining. Serum total tryptase measurement may aid in the diagnostic workup; levels above 20 ng/mL suggest systemic mastocytosis, whereas values below 14 ng/mL are more commonly observed in cutaneous disease or in individuals without mast cell disorders. Depending on the clinical context, additional investigations may be warranted to assess extracutaneous involvement.[1]

Management of cutaneous UP is symptomatic, as no curative therapy currently exists. Second-generation non-sedating H1-antihistamines represent first-line treatment, whereas phototherapy (psoralen plus ultraviolet A or narrowband ultraviolet B) may be considered in extensive or refractory cases.[10]

Conclusion

Despite the uncommon coexistence of HIV infection and UP, current evidence remains insufficient to establish a causal relationship, and further studies are required to clarify the potential association between these conditions.

Funding

None.

Conflicts of interest

None.

Ethical considerations

Protection of human subjects and animals. The authors declare that no experiments on humans or animals were performed for this research.

Confidentiality, informed consent, and ethical approval. The authors have followed their institution's confidentiality protocols, obtained informed consent from all patients, and secured approval from the Ethics Committee. SAGER guidelines have been followed as applicable to the nature of the study.

Declaration on the use of artificial intelligence. The authors declare that no generative artificial intelligence was used in the writing or creation of the content of this manuscript.

References

1. Brockow K. Urticaria pigmentosa. Immunol Allergy Clin North Am. 2004;24:287-316, vii.
2. Soilleux EJ, Grills C, Cooper SM. Cutaneous mastocytosis in human immunodeficiency virus: an unfortunate coincidence? Clin Exp Dermatol. 2008;33:619-21.
3. Azaña JM, Torreló A, Matito A. Update on mastocytosis (Part 1): pathophysiology, clinical features, and diagnosis. Actas Dermosifiliogr. 2016;107:5-14.
4. Madigan LM, Boggs NA, Rets AV, Gru AA, Tashi T, Wada DA, et al. Mastocytosis in the skin: approach to diagnosis, evaluation, and management in adult and pediatric patients. Am J Clin Dermatol. 2025;26:499-510.
5. Stojanović S, Brkić S, Jovanović M, Vučković N. Urticaria pigmentosa in a patient with acquired immunodeficiency syndrome: a case report. Serb J Dermatol Venereol. 2011;3:113-20.
6. Elsaiey A, Mahmoud HS, Jensen CT, Klimkowski S, Taher A, Chaudhry H, et al. Mastocytosis: a review of disease spectrum with imaging correlation. Cancers (Basel). 2021;13:5102.
7. Sundstrom JB, Ellis JE, Hair GA, Kirshenbaum AS, Metcalfe DD, Yi H, et al. Human tissue mast cells are an inducible reservoir of persistent HIV infection. Blood. 2007;109:5293-300.
8. Jiang AP, Jiang JF, Guo MG, Wei JF, Qin Y, Guo QQ, et al. Human mucosal mast cells capture HIV-1 and mediate viral trans-infection of CD4+ T cells. J Virol. 2016;90:2928-37.
9. Witczak P, Brzezińska-Błaszczyk E. Are mast cells the Trojan horse in HIV-1 infection? Cent Eur J Immunol. 2013;38:531-35.
10. Theoharides TC, Valent P, Akin C. Mast cells, mastocytosis, and related disorders. N Engl J Med. 2015;373:163-72.