Portuguese Journal of Dermatology and Venereology

Permanyer

Check for updates

DERMATOLOGY IMAGES

A reddish-brown nodule in a human immunodeficiency virus-positive patient

Nódulo vermelho-acastanhado num doente com VIH

Beatriz F. Vilela[1], Pedro Simões Farinha[1], Ana Ferreirinha[1,2], Alexandre João[1], and Cândida Fernandes[1]*

[1]Department of Dermatology and Venereology, Hospital de Santo António dos Capuchos, Unidade Local de Saúde de São José; [2]Department of Dermatology and Venereology, NOVA Medical School, NOVA University Lisbon. Lisbon, Portugal

A 31-year-old man living with human immunodeficiency virus (HIV), receiving regular antiretroviral therapy with stable CD4 counts, presented with an asymptomatic papule on the posterior aspect of the left thigh. Over 8 months, it progressively enlarged to approximately 4 cm. Examination revealed a firm, well-demarcated reddish-brown nodule with a smooth surface and no regional lymphadenopathy (Fig. 1). Dermoscopy showed a central homogeneous pigmented area with slightly erythematous peripheral areas and dotted vessels, raising the differential diagnoses of amelanotic melanoma, Kaposi sarcoma, and cutaneous pseudolymphoma.

An excisional biopsy was performed. Histopathological examination revealed a dermal tumor composed of monomorphic spindle cells, with extensive erythrocyte extravasation and abundant hemosiderin deposition, without significant cytological atypia or increased mitotic activity (Fig. 2). Immunohistochemistry showed partial factor XIIIa expression and negativity for CD34, HHV-8, and Melan-A, helping to exclude the main differential diagnoses and supporting a diagnosis of hemosiderotic dermatofibroma.

Hemosiderotic dermatofibroma is an uncommon variant of cutaneous fibrous histiocytoma that can clinically mimic vascular and melanocytic neoplasms.[1-3] In patients living with HIV, Kaposi sarcoma is a particularly important consideration. Complete surgical excision is generally curative, although local recurrence may occur.[1,2] This case highlights the importance of clinicopathological correlation in atypical pigmented or vascular-appearing nodules, particularly in clinical contexts that broaden the differential diagnosis.



Figure 1. Solitary, well-demarcated reddish-brown nodule on the posterior aspect of the left thigh.

***Correspondence:**
Beatriz F. Vilela
E-mail: beamfvilela@gmail.com

Received: 26-08-2026
Accepted: 20-10-2026
DOI: 10.24875/PJDV.26000116

Available online: **16-11-2026**
Port J Dermatol and Venereol. **(ahead of print)**
www.portuguesejournalofdermatology.com

2795-501X / © 2026 Portuguese Society of Dermatology and Venereology. Published by Permanyer. This is an open access article under the CC BY-NC-ND license (http://creativecommons.org/licenses/by-nc-nd/4.0/).

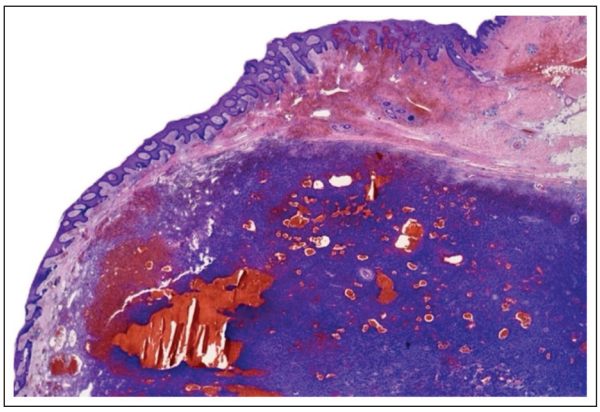

Figure 2. Histopathological examination showing a dermal spindle-cell proliferation with extensive erythrocyte extravasation and hemosiderin deposition (H&E; ×40).

Funding

None.

Conflicts of interest

None.

Ethical considerations

Protection of human subjects and animals. The authors declare that no experiments on humans or animals were performed for this research.

Confidentiality, informed consent, and ethical approval. This study does not involve personal patient data, medical records, or biological samples, and does not require ethical approval. SAGER guidelines do not apply. Written informed consent for publication of this case report and associated images was obtained from the patient.

Declaration on the use of artificial intelligence. The authors declare that no generative artificial intelligence was used in the writing or creation of the content of this manuscript.

References

1. Lagziel T, Sylvester S, Hultman CS, Asif M. Hemosiderotic dermatofibroma: a rare and atypical variant capable of clinically resembling melanoma. Cureus. 2020;12:e6736.
2. Nishimoto A, Ito K, Usami S, Ogawa R, Akaishi S, Ansai SI. 168 cases of aneurysmal dermatofibroma and 29 cases of hemosiderotic dermatofibroma: a clinicopathologic study. Am J Clin Pathol. 2024;161:232-44.
3. Şenel E, Yuyucu Karabulut Y, Doğruer ğenel S. Clinical, histopathological, dermatoscopic and digital microscopic features of dermatofibroma: a retrospective analysis of 200 lesions. J Eur Acad Dermatol Venereol. 2015;29:1958-66.